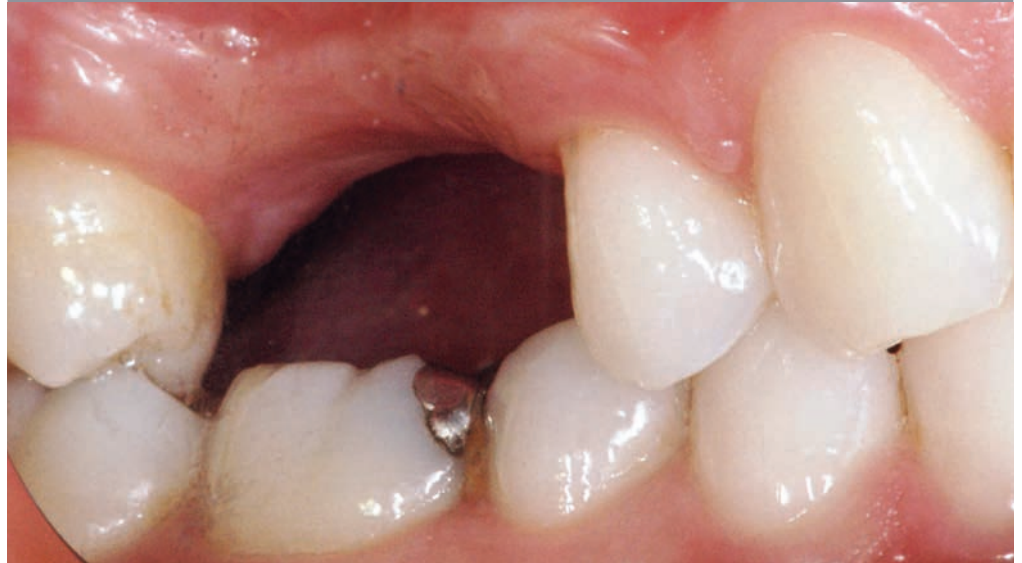

# Vertical Augmentation



Therapy concept of Prof. Matteo Chiapasco, University of Milan, Italy

> Vertical ridge augmentation with autogenous bone, Geistlich Bio-Oss® and Geistlich Bio-Gide®



## 1. Indication profile

<b>Region</b>	<input checked="" type="checkbox"/> aesthetic region	<input type="checkbox"/> non-aesthetic region
	<input type="checkbox"/> single tooth gap	<input checked="" type="checkbox"/> multiple tooth gap
<b>Bony situation</b>	<input checked="" type="checkbox"/> bone defect present	<input type="checkbox"/> no bone defect present
<b>Soft tissue situation</b>	<input type="checkbox"/> recession	<input checked="" type="checkbox"/> no recession
	<input type="checkbox"/> inflamed	<input type="checkbox"/> infected
	<input type="checkbox"/> thick biotype	<input checked="" type="checkbox"/> thin biotype
	<input checked="" type="checkbox"/> primary wound closure possible	<input type="checkbox"/> primary wound closure not possible
<b>Implantation</b>	<input checked="" type="checkbox"/> intact papillae	<input type="checkbox"/> impaired, missing papillae
	<input checked="" type="checkbox"/> adequate keratinised mucosa	<input type="checkbox"/> inadequate keratinised mucosa
	<input type="checkbox"/> simultaneously with bone augmentation (1 step)	<input type="checkbox"/> uneventful
	<input checked="" type="checkbox"/> successively to bone augmentation (2 steps)	

## Background information

Dr. Matteo Chiapasco:

A 40-year old male, healthy and non-smoker, was referred for assessment of the possibility to restore the missing dentition in the maxillary arch (teeth 16 and 15) with an implant-supported fixed partial prosthesis. Initial clinical and radiographic (panoramic and intraoral radiographs) examination revealed however, that a vertical and horizontal bone defect was present (Figures 1-4). Moreover, the patient had a high smile line in the posterior maxilla on both sides (Figures 5-6), high aesthetic expectations, and did not accept any compromise in terms of the final outcome of the prosthetic restoration. In order to optimize the final outcome, consultation with the prosthodontist was requested. Impressions were taken and, on the plaster model obtained, a waxing-up was performed. Placing teeth in the ideal position, a discrepancy appeared between the residual bone and the final restoration (Figure 7).

The CT scans done with a diagnostic template including radiopaque landmarks constructed on the waxing-up confirmed resorption of the alveolar ridge at the level of the missing dentition, both in the vertical and horizontal dimension. This situation precluded the possibility of placing implants in a proper, prosthetically driven position. Obtaining an adequate restoration of the missing dentition from a functional, and specifically from an aesthetic point of view was challenging (Figures 8-9).

The surgical plan first included a reconstruction with autologous bone blocks taken from the mandibular ramus, in association with the use of bovine bone mineral (Geistlich Bio-Oss®, Geistlich Biomaterials, Wolhusen, Switzerland) and a native resorbable collagen membrane (Geistlich Bio-Gide®, Geistlich Biomaterials, Wolhusen, Switzerland) to correct both vertically and horizontally the deficient alveolar ridge and to facilitate bone gain over time (Figures 9-20). Placement of 2 implants was planned in a second stage procedure, 4 months later (Figures 21-25). Finally, after another three month period, the prosthetic restoration was started. After another 3 month period necessary to condition soft tissues, the final prosthesis was delivered (Figures 26-29). A radiographic control 2 years later showed stability of periimplant bone (Figure 30).

## 2. Aims of the therapy

- > Restore adequate bone volume of the edentulous ridge.
- > Optimize intermaxillary relationships.
- > Optimize the final prosthetic result from a functional and aesthetic point of view.

## 3. Surgical procedure

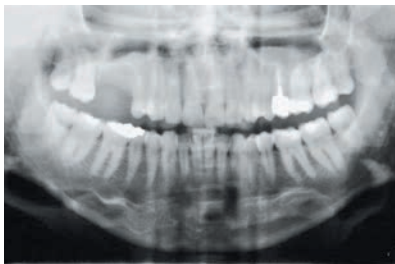


Fig. 1 Preoperative panoramic radiograph showing missing dentition at level 15-16.

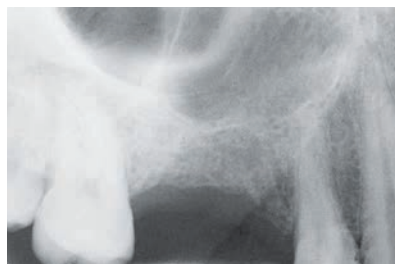

Fig. 2 Preoperative intraoral radiograph shows apparently enough bone below the sinus to allow placement of two short implants at least 6 mm long.

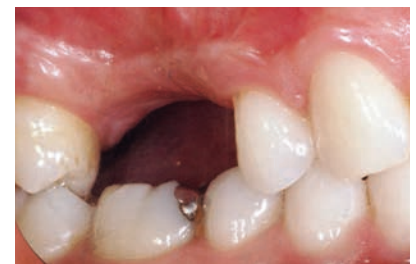

Fig. 3 Intraorally, a moderate vertical resorption of the alveolar ridge is visible.

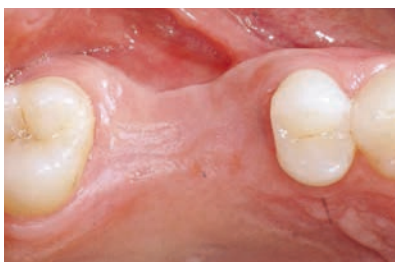

Fig. 4 Moderate horizontal resorption of the ridge is also visible.

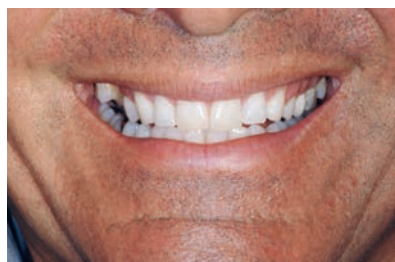

Fig. 5 The high smile line in the posterior maxilla and the high aesthetic expectations of the patient, contraindicate the use of short implants with longer crowns. This would create a relevant "asymmetry" in teeth length on the right and left sides, with a less than ideal result.

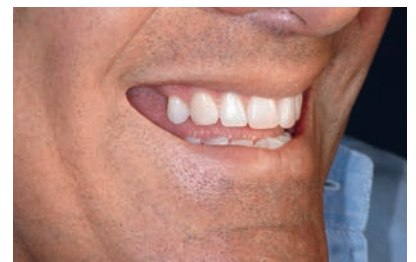

Fig. 6 Lateral view of the smile line on the right side shows vertical resorption of the alveolar ridge behind tooth 14.

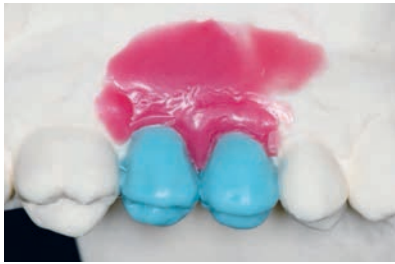

Fig. 7 Preoperative waxing-up demonstrates that a reconstruction of the resorbed alveolar ridge is necessary, to maintain the teeth to be prosthetically restored with appropriate dimensions (length, in particular) compared to the neighboring dentition and to the corresponding teeth on the opposite side.



Fig. 8 A diagnostic template is fabricated following the indications of the pre-op waxing-up.

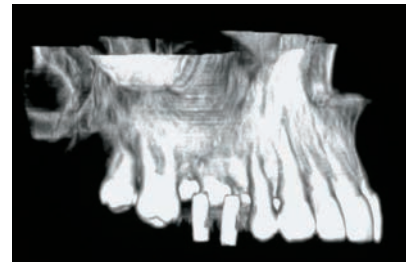


Fig. 9 CT scan performed with the diagnostic template in the mouth confirmed the bone defect between the ideal position of prosthetic crowns and the residual alveolar bone. Without reconstruction, the implant would be placed too far apically and palatally, thus rendering the final prosthetic result mediocre.

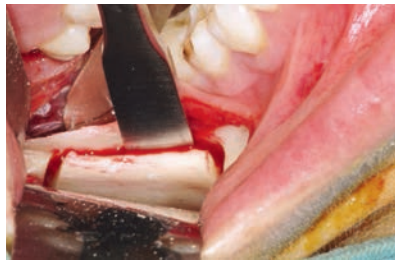

Fig. 10 To harvest an autogenous bone block from the mandibular ramus for the reconstruction of the maxillary defect, a full thickness flap is raised after an incision which follows the ascending ramus of the mandible. The ascending ramus is exposed, an autogenous bone segment is outlined with fissure burs assembled on a low-speed straight handpiece, and finally it is detached with the aid of a surgical chisel.

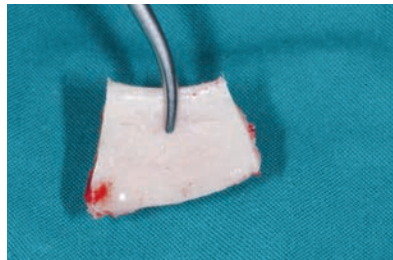


Fig. 11 The bone segment harvested from the ramus must be shaped now according to the bone morphology of the recipient bed.

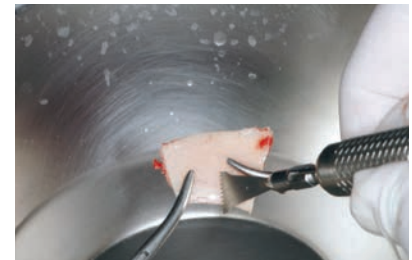

Fig. 12 An oscillating saw is used to separate the block in different pieces. Two pieces will be used as blocks for the vertical and horizontal reconstruction. One piece will be transformed into particulated bone.

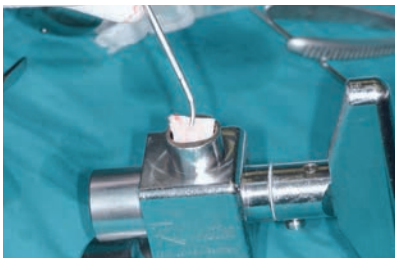

Fig. 13 Transformation into particulated bone is obtained by means of a bone microtome.

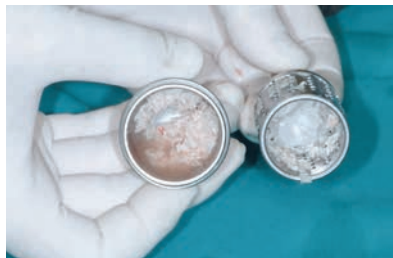

Fig. 14 The autogenous bone chips obtained after particulation of a bone block. The particulated bone will be used to "pack" every empty space between the recipient site and the bone blocks and to cover "steps" between the graft margins and the recipient bed.

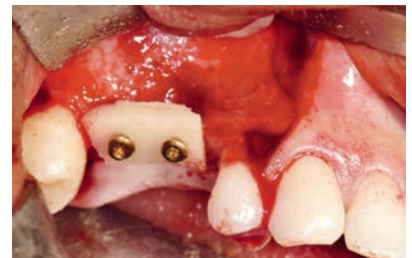


Fig. 15 After elevation of the mucoperiosteal flap, the maxillary defect is exposed and a first block of autogenous cortical bone is stabilized with two titanium microscrews to correct the vertical defect.

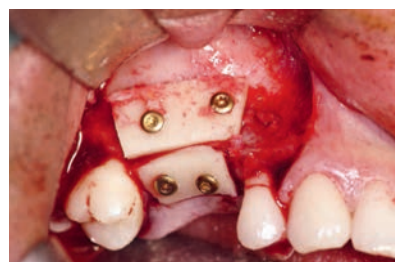

Fig. 16 A second block is fixed in the same manner to correct the horizontal defect. Any gap between the recipient site and the blocks must be filled with particulated autogenous bone, to avoid penetration of connective, fibrous tissue during healing which may compromise the graft integration.

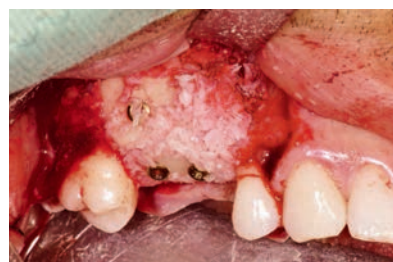

Fig. 17 A mixture of autogenous particulated bone and bovine bone mineral (Geistlich Bio-Oss®) is used to cover the bone blocks and to cover steps between the margins of the grafts and the recipient bed. This procedure will simplify the contouring of the graft.

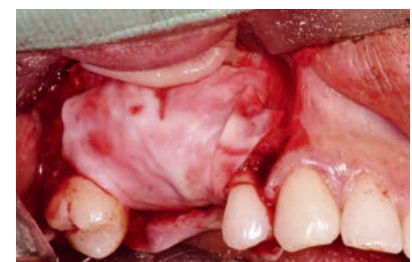

Fig. 18 The grafts (blocks and particulated bone + Geistlich Bio-Oss®) are covered with a resorbable collagen membrane (Geistlich Bio-Gide®) in order to stabilize the particulated graft and to reduce the risk of bone resorption.



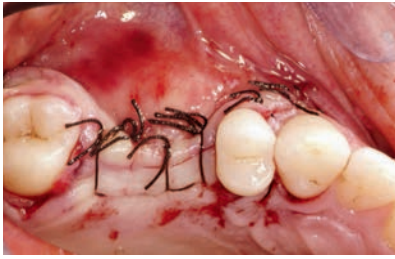

Fig. 19 A tension-free and water-tight suture has been performed to prevent dehiscence of the surgical wound and potential contamination of the grafted area, which may otherwise lead to complete loss of the graft.

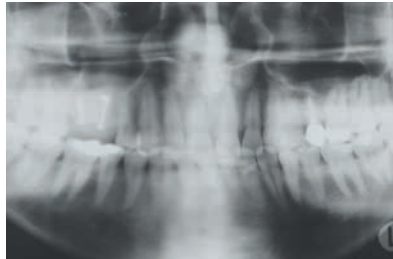


Fig. 20 Postoperative radiographic control immediately after the reconstruction showing the augmentation obtained.

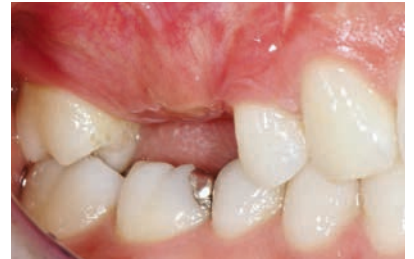

Fig. 21 Clinical control three months after surgery: an excellent correction of the defect and the proper intermaxillary relationship is clearly visible.

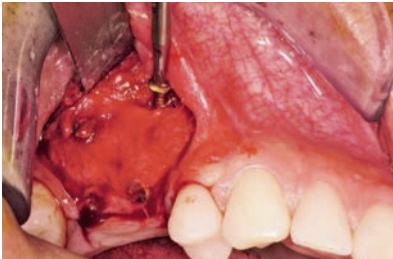


Fig. 22 Four months afterwards, the patient is ready to receive implants. After the elevation of a partial thickness, epiperiosteal flap, not to expose the underlying graft, fixation screws are removed.

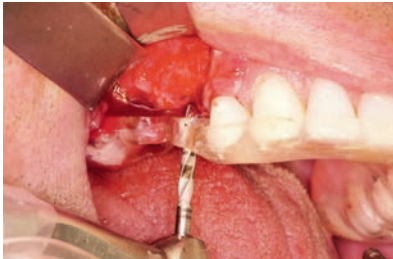


Fig. 23 Following the indications of the previously fabricated template, implant sites (2) are prepared in a prosthetically driven and optimal position.

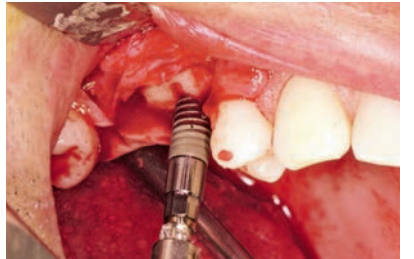


Fig. 24 Two implants, 4.1 mm in diameter and 10 mm in length (Straumann Bone level implants, Institut Straumann, Basel, Switzerland), are inserted in the reconstructed area.

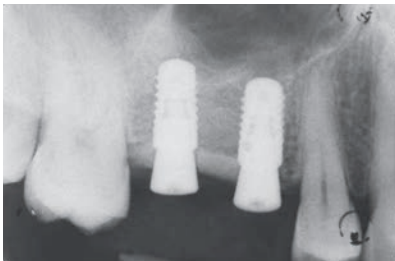


Fig. 25 Radiographic control immediately after implant placement.

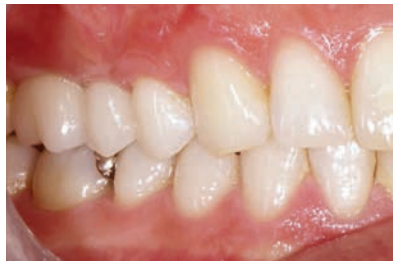

Fig. 26 The final prosthetic result showing optimal occlusion and morphology of the implant-supported crowns.

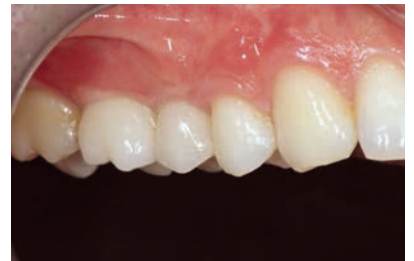

Fig. 27 Close-up of the implant-supported restoration of teeth 15 and 16, with very good integration with the neighboring dentition.

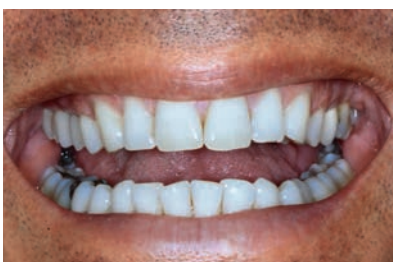

Fig. 28 During patient's smile, an almost perfect symmetry is visible between the reconstructed and prosthodontically restored site and the contralateral one with natural dentition.

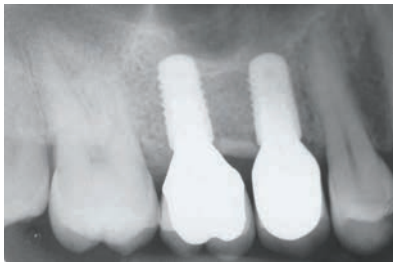


Fig. 29 Radiographic control after the completion of the restorative procedure.

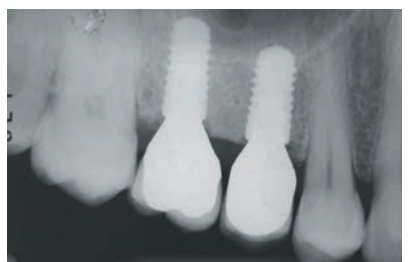

Fig. 30 Radiographic control two years after the completion of the prosthetic rehabilitation, showing stability of implants and the periimplant transplanted bone.

## Literature references

---

- <sup>1</sup> Triplett, R.G. & Schow, S.R. (1996) Autologous bone grafts and endosseous implants: complementary techniques. *International Journal of Oral and Maxillofacial Surgery* 54:486-494.
  - <sup>2</sup> Maiorana, C., Beretta, M., Salina, S., & Santoro, F. (2005) Reduction of autogenous bone graft resorption by means of Bio-Oss® coverage: a prospective study. *International Journal of Periodontics and Restorative Dentistry* 25(1):19-25.
  - <sup>3</sup> Hämmerle, C.H., Jung, R.F. & Feloutzis, A. (2002) A systematic review of the survival of implants in bone sites augmented with barrier membranes (guided bone regeneration) in partially edentulous patients. *Journal of Clinical Periodontology* 29:226-231.
  - <sup>4</sup> Levin, L., Nitzan, D. & Schwartz-Arad, D. (2007) Success of dental implants placed in intraoral block bone grafts. *Journal of Periodontology* 78: 18-21.
  - <sup>5</sup> Chiapasco, M., Abati, S., Romeo, E. & Vogel, G. (1999) Clinical outcome of autogenous bone blocks or guided bone regeneration with e-PTFE membranes for the reconstruction of narrow edentulous ridges. *Clinical Oral Implants Research* 10:278-288.
  - <sup>6</sup> Chiapasco, M., Casentini, P. & Zaniboni, M. (2009) Bone augmentation procedures in implant dentistry. *International Journal of Oral and Maxillofacial Implants* 24(suppl):237-259.
- 

## Contact

---

- > Unit of Oral Surgery - Department of Health Sciences, University of Milan, Italy  
telephone: +39 02 50319000, fax: +39 02 50319040, e-mail: [matteo.chiapasco@unimi.it](mailto:matteo.chiapasco@unimi.it), website: [www.matteochiapasco.com](http://www.matteochiapasco.com)
- 

## Suppliers (used suture material, medication, implant system etc.)

---

- > Bovine bone mineral: Geistlich Bio-Oss® by Geistlich Biomaterials, Wolhusen, Switzerland
  - > Collagen membrane: Geistlich Bio-Gide® by Geistlich Biomaterials, Wolhusen, Switzerland
  - > Implants: Straumann Bone level implants by Institut Straumann AG, Basel, Switzerland
- 

## Other indication sheets

---

- > To receive indication sheets free of charge, please visit our website: [www.geistlich.com/indicationsheets](http://www.geistlich.com/indicationsheets)
- > If you do not wish to receive our indication sheets any longer, please unsubscribe at your local distributor.

**Geistlich**  
**Biomaterials**

©Geistlich Pharma AG  
Business Unit Biomaterials  
CH-6110 Wolhusen  
phone +41 41 492 56 30  
fax +41 41 492 56 39  
[www.geistlich-pharma.com](http://www.geistlich-pharma.com)