


MAJOR BONE AUGMENTATIONS.

What techniques are most suitable?
Will there soon be brand new techniques?



Major Bone Augmentations: Contemporary techniques and materials



Prof. Hendrik Terheyden | Germany
Clinic for Oral and Maxillo-Facial Surgery
Red Cross Hospital, Kassel

Nowadays, using modern biomaterials and autologous bone transplants, it is possible to place implants in patients experiencing considerable bone deficits – if appropriate surgical techniques are used and the patient's circumstances permit.

Bone augmentations are no longer just performed to allow thorough osseointegration of dental implants. They are also used to enhance the:

1. Aesthetics,
2. Prosthetic function, and
3. Prognosis for the restoration.

For example, augmentation can help avoid unnaturally long crowns in the mesial maxilla **(1)** and impression difficulties or eccentric screw channels with non-axially aligned implants **(2)**. If adequately sized implants are covered by bone on all sides, they have a good prognosis – both mechanically and biologically **(3)**.

For instance, in an edentulous maxilla it can be important to use bone aug-

mentation to facilitate good prosthetic function in tetrapodal or hexapodal prosthetic support with large antero-posterior abutment spread and a large support polygon. In an edentulous,

implants will not be aligned along the axis of the prosthesis and mediatory, so that awkward prosthetic structures are required. A proper augmentation, however, builds the bone where it is needed

TAB. 1: WHAT NEEDS TO BE TAKEN INTO ACCOUNT?

| | |
|-------------------------|--|
| Contraindications | Medication with bisphosphonates or other antiresorptive agents, tumour radiation |
| Indication restrictions | General factors like smoking, diabetes mellitus |

atrophied jaw a bone augmentation can normalise the occlusal position and the integrity of the mimic facial muscles and so improve facial aesthetics. Augmentation surgery can be complex. When planning surgery, indication restrictions use and contraindications need to be taken into account **(Tab. 1)**.

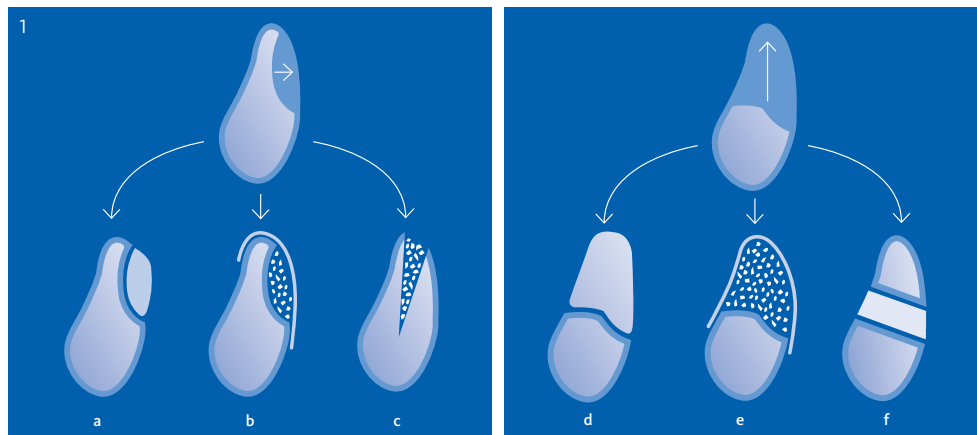
Avoiding compromises

Although it is sometimes possible to compromise by using implant prostheses with implants that are dimensionally-reduced, angled or anchored to the cheekbone, it can be assumed that implant planning will then often be bi-directional. In other words, the

to fit the prosthetic tooth axis. This allows implants to be planned unidirectionally with a correspondingly dedicated crown-bridge prosthesis.

Augmentation techniques

Depending upon the defect type, inlay, interpositional, appositional and onlay osteoplasties can be used **(Fig. 1)**. The degree of surgical complexity grows correspondingly because it becomes increasingly complex to reliably cover the bone transplants with soft tissue and avoid a subsequent dehiscence. The more difficult the defect class, the more active the bone transplant itself has to be. But beware that using autol-



1 Augmentation techniques

Horizontal

- a Appositional osteoplasty with block
- b Appositional osteoplasty with granulate and membrane
- c Inlay osteoplasty

Vertical

- d Onlay osteoplasty with block
- e Onlay osteoplasty with granulate and rigid membrane
- f Interpositional osteoplasty

ogous chips from a bone filter increases the chance for infection, necessitating a good antibacterial regimen and an antiseptic procedure.

Challenge: angiogenesis

Today it is not yet clinically predictable to provide vertical augmentation with blocks made of bone replacement material. This is in part due to angiogenesis. Since vascularization occurs only a few vertical millimeters from the bone substrate. Biomaterial which is further than 3 to 4 mm away from the bone substrate tends to heal with scarring.

Sandwich technique and bone splitting

An internal bone defect presents the possibility for the good healing tendencies of inlay and interpositional osteoplasties (sandwich) with angiogenesis from all sides of the graft. Internal bone defects occur when, for example, a vertical defect is transformed into a sandwich osteoplasty by a horizontal osteotomy or when a horizontal defect is carried over into bone splitting.

A major advantage of sandwich-interpositional osteoplasties compared to appositional and onlay osteoplasties is

that the soft tissue remains attached to the alveolar ridge and does not need to be shifted in a lingual direction. This facilitates soft tissue coverage, improves peri-implant tissue and reduces the likelihood of resorption (**Fig. 2**). A modification of the sandwich osteoplasty is a Schwing interposition, which allows a ridge to be raised and broadened, if moderately atrophied knife-edge ridges are involved (**Fig. 3**).

Problem: transplant resorption

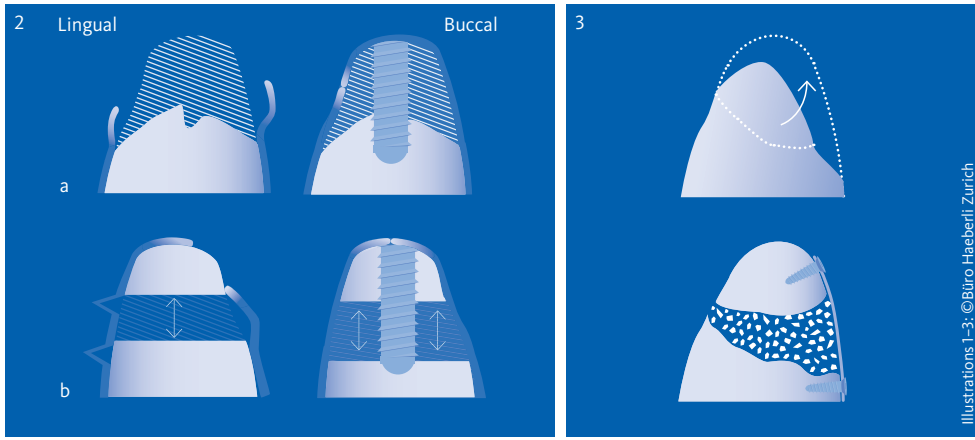
Free bone transplants – whether cancellous or cortical – can permanently heal only through internal bone resorption and subsequent reconstruction (“creeping substitution”). Whereas internal resorption of bone is necessary for the transformation, surface resorption on a larger scale is undesirable because it causes the augmentation material to lose volume and produces clinically unpredictable results. Thus, resorption occurs in about 40% of cases with large pelvic bone transplants¹, particularly early in the healing process. To counteract this uncontrolled resorption, autologous bone blocks can be covered with Geistlich Bio-Oss® and Geistlich Bio-Gide®. Geistlich Bio-Oss® inhibits osteoclast precursor cells,

while Geistlich Bio-Gide® forms a barrier against soft tissue in-growth without inhibiting vascularisation, which is crucial for new bone formation^{2,3}.

Augmentation materials containing Geistlich Bio-Oss® exhibit volume preservation for many years⁴.

Long term prognosis

Implants in augmented bones have an excellent five-year survival rate, which is generally as good as native bone or over 95%⁵. Cone beam computed tomography (CBCT) studies have provided excellent prospective proof of the constancy of volume with alveolar ridge augmentations both for bone blocks and for the membrane (GBR) technique over five years^{6,7}. Even major augmentations like Le Fort 1 interpositional osteoplasties exhibit an implant survival rate of 94.5%⁸.



- 2 Vertical augmentation techniques**
- a Bilateral onlay osteoplasty: the attached gingiva is displaced in a lingual direction as it must be completely mobilized to cover the transplant.
 - b Interpositional osteoplasty (formerly distraction osteogenesis): the attached gingiva is not displaced
- 3 Schwing interposition** enables a ridge to be raised and broadened if moderately atrophied knife-edge ridges are involved.

The augmented volume remains stable over the long-term when implants are subjected to stress from chewing, as ten-year studies have shown^{9,10}. On the other hand, the augmentation is 100% resorbed if it does not undergo normal stress from masticatory function¹¹. Nowadays, using augmentation surgery, experienced surgeons are able to obtain very reliable results. In the future, new techniques, such as tissue engineering, could reduce surgical complexity and morbidity.

References

- 1 Chiapasco M, et al.: Int J Oral Maxillofac Implants 2009; 24 Suppl: 237-59.
- 2 Wiltfang J, et al.: Clin Oral Implants Res 2014; 25(2): e127-32.
- 3 Schwarz F, et al.: Clin Oral Implants Res 2008; 19(4): 402-15.
- 4 Buser D, et al.: J Dent Res 2013; 92(12 Suppl): 176S-82S.
- 5 Jansen JA, Terheyden H: Int J Oral Maxillofac Implants 2009; 24 Suppl: 218-36
- 6 Jung RE, et al.: Clin Oral Implants Res 2013 Dec 2. [Epub ahead of print]
- 7 Pieri F, et al.: Int J Oral Maxillofac Implants 2013; 28(1): 270-80.
- 8 Chiapasco M, et al.: Clin Oral Implants Res 2007; 18(1): 74-85.
- 9 Boven GC, et al.: Int J Oral Maxillofac Surg 2014; 43(5): 626-32.
- 10 Stellingsma K, et al.: Clin Oral Implants Res 2014; 25(8): 926-32.
- 11 Sbordone C, et al.: J Oral Maxillofac Surg 2012; 70(11): 2559-65.

Autologous graft or Geistlich Bio-Oss®?

| INLAY OSTEOPLASTY | INTERPOSITIONAL OSTEOPLASTY | HORIZONTAL APPositionAL OSTEOPLASTY | VERTICAL ONLY OSTEOPLASTY |
|---|--|---|--|
| <ul style="list-style-type: none"> › Can be accomplished with Geistlich Bio-Oss® (granulate or collagen), Geistlich Bio-Gide® for coverage and shielding against soft tissue | <ul style="list-style-type: none"> › A mixture of autologous bone and Geistlich Bio-Oss®, coverage with Geistlich Bio-Gide® › Alternatively, Geistlich Bio-Oss® Block or Geistlich Bio-Oss® Collagen › Autologous bone blocks: filling the gaps/contouring with Geistlich Bio-Oss®, coverage with Geistlich Bio-Gide® | <ul style="list-style-type: none"> › Autologous bone chips mixed with Geistlich Bio-Oss®, Geistlich Bio-Gide® for stabilising and lessening the risk of complication › If defects are larger, bone block and Geistlich Bio-Gide®, Geistlich Bio-Oss® for block contouring | <ul style="list-style-type: none"> › Active autologous block transplants, e.g., from the pelvis or skull › Particulate bone chips, coverage with rigid membrane › Geistlich Bio-Oss®, as required, for block contouring or mixed with bone chips › Geistlich Bio-Gide®, as required, over the rigid membrane to lower the rate of dehiscence |

Horizontal augmentations using granulate material



Prof. Istvan Urban | Hungary/USA

Department of Periodontology at the University of Szeged, School of Dentistry
Dental School at the Loma Linda University, California

Interviewed by Claudia Bühlmann

Granulate graft material has to be well stabilised, and Geistlich Mucograft® can be combined with a gingival strip graft. Prof. Istvan Urban explains his techniques.

Professor Urban, you use granulate graft material for horizontal ridge augmentations. Why?

Prof. Urban: I never liked using the autogenous bone block, because I found them very invasive to harvest and sometimes very complicated to adapt perfectly to host bone. Another disadvantage is the resorption that we usually see in blocks.

Today we prefer particulate graft materials for two main reasons: Firstly, our histological examinations show that they are easily vascularised, which is very important for graft incorporation and new bone formation. Secondly, the particles adapt to any surface irregularities.

However, we have to completely immobilise the graft and cover the granules. In the beginning, we used non-resorbable, titanium-reinforced membranes for both horizontal and vertical aug-

mentations. The membranes worked well, but they were sometimes very demanding and not well accepted by many clinicians.

Then we asked ourselves why not use the remaining bony wall in a smarter way. We started to apply resorbable, rigid membranes for horizontal augmentations with good results. Today we are using a native collagen membrane, the Geistlich Bio-Gide®.

Why have you called your approach the “sausage technique”?

Prof. Urban: We fix the collagen membrane with titanium pins into the bone walls and fill the space under the membrane to form a very stable graft. The whole graft looks like a densely filled sausage. Geistlich Bio-Gide® acts like an immobilised “sausage” skin during the early weeks of healing.

What are your results?

Prof. Urban: We get very predictable results with this technique using a 1:1 mixture of Geistlich Bio-Oss® and autogenous bone particles. We can usually harvest enough bone using bone scrapers. The Geistlich Bio-Oss® particles incorporate well and help to reduce graft resorption. This has been nicely demonstrated both clinically and histologically in our recent prospective case series¹.

“A membrane should allow vascularisation from the periosteum.”

What properties should a membrane have for this procedure?

Prof. Urban: First, I think a membrane should allow vascularisation from the periosteum. This enables nutrient transfer, capillary in-growth and other potential stimulating effects. The elasticity of a membrane is also important, so that I can stretch it when I fix it with the pins and form the stable “sausage bone graft”. The membrane should disappear in a good prompt manner so that it does not interfere with bone maturation. I do not think a long resorption time is needed, and it may even slow down bone formation.

Geistlich Bio-Gide® has all these properties. The lack of titanium reinforcement can be overcome reliably by fixing the membrane both lingually or palatally and vestibularly. Today we use titanium-reinforced membranes exclusively for vertical defects.

I also think that we understand the principle of Guided Bone Regeneration much better now than 20 years ago, when we believed long resorption times were necessary. The interaction with the periosteum might be a very important part of good bone maturation, and this is better when native collagen membranes are used.

What complications have you faced so far with the sausage technique?

Prof. Urban: In the past ten years I have had only one posterior mandibular case in which the patient developed a postoperative infection¹. I can only blame myself for this complication as I think the infection emerged from a third molar, which I should have extracted. Anyway, in general, the procedure is very successful and predictable. We can even reconstruct completely resorbed maxillary edentulous ridges using this technique. But of course, adequate patient preparation and post-op management as well as precise surgical techniques are key factors in reducing the rate of any complication.

Soft tissue management is often a problem in horizontal augmentations. How do you handle this?

Prof. Urban: Advanced ridge augmentation procedures usually result in a severe displacement of the mucogingival line and vestibular loss. In the past we performed mucogingival surgery using epithelialised gingival grafts or free connective tissue grafts. We left these grafts to heal in an open healing environment because this is a prerequisite for the reformation of the vestibule and keratinised tissue. Graft harvesting from the palatal mucosa, however, may be associated with significant patient morbidity. This was usually the treatment phase that patients did not like at all. When we

heard of Geistlich Mucograft[®], we were very interested in it because we saw

“Graft harvesting from the palatal mucosa may be associated with significant patient morbidity.”

potential for soft tissue regeneration – and because I was fed up with the big connective tissue grafts.

How do you use Geistlich Mucograft[®] to regenerate soft tissue?

Prof. Urban: First, I had to understand how the collagen matrix works: I like to think of it as a “cell collector”, which means it collects tissue cells from the neighbouring soft tissue. If the neighbouring tissue is only mucosa or mostly mucosa, we won’t regenerate more than just a few millimetres of keratinised tissue. Therefore, we had the idea to combine the matrix with an apically positioned autogenous strip gingival graft. The strip graft was originally described by my former teachers Dr. Thomas Han and Henry Takei, so I was very familiar with it. By placing the strip graft on the apical end of the surgically created bed, we expected it to act as a barrier for the apical tissues of the alveolar mucosa, which are not capable of keratinising. In this manner, the tissues from the lateral borders and from the strip graft would migrate and differentiate into keratinised mucosa within this three-dimensional scaffold of the matrix.

What are your experiences with the strip technique?

Prof. Urban: In a study of a prospective case series, which is now accepted for publication, we found that we could in fact regenerate the amount of keratinised tissue needed. We achieved an average of 6.3 mm of keratinised tissue after one year. In the anterior maxilla, which was one of the major indications, it was even 7.8 mm. We also found very favourable results for pain intensity: on a visual analogue scale of up to 10 – with 10 being the strongest pain – the average pain in the first week was 2.3, and it was 0 for the following weeks of healing. Ten out of the 20 patients did not take any pain medication, and one patient only needed medication for the palatal wound.

What are the clinical prerequisites for using these techniques?

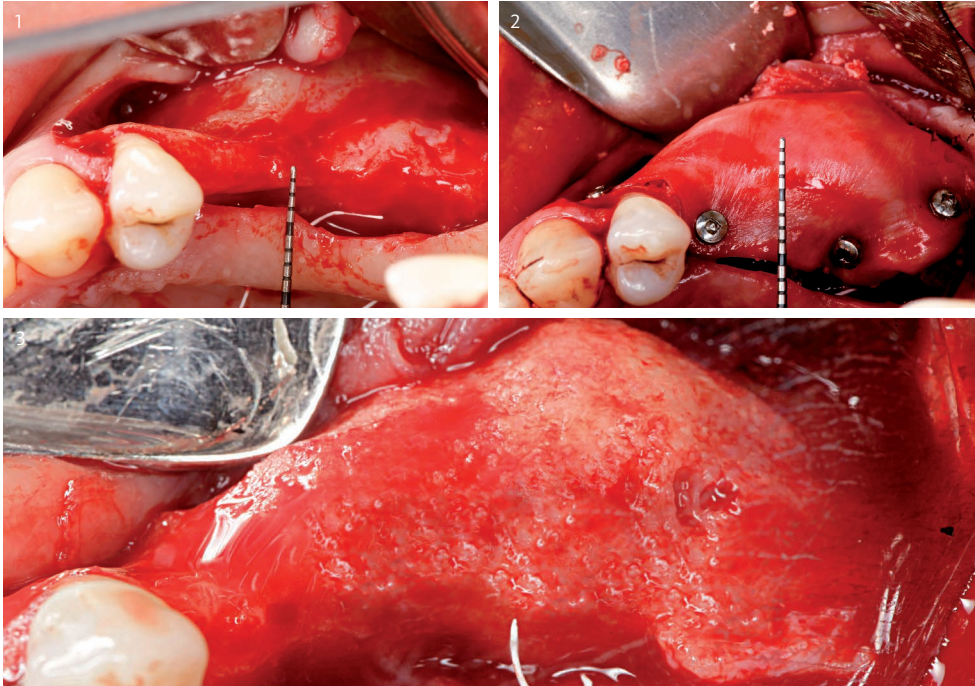
Prof. Urban: I like things to be both simple and reproducible. Both the sausage technique and the strip technique using Geistlich Mucograft[®] are easy for clinicians with adequate surgical skills. Surgeons, however, should train for the techniques in hands-on courses. Live surgery and video tutorials will also help them to become more familiar with these options for tissue regeneration.

Professor Urban, thank you very much for this interview!

References

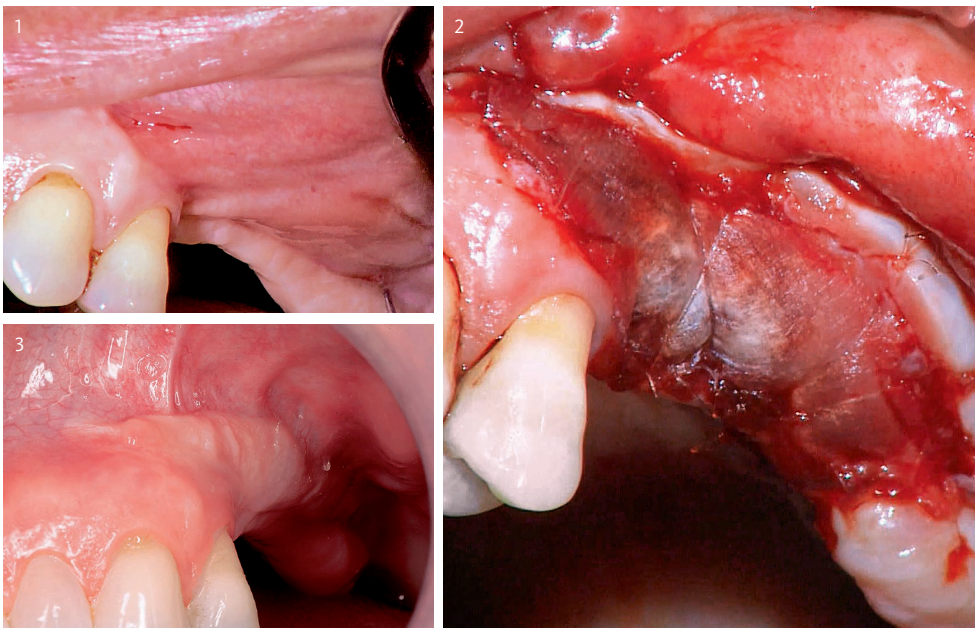
- 1 Urban IA, et al: Int J Periodontics Restorative Dent 2013; 33(3): 299-307.

SAUSAGE TECHNIQUE



- 1 Intraoperative view demonstrates insufficient ridge width
- 2 Geistlich Bio-Gide® is applied over a mixture (1:1) of bone chips from the retromolar area, and Geistlich Bio-Oss® is rigidly fixed with pins.
- 3 Sufficient amount of augmented bone for implant placement after 8 months.

STRIP TECHNIQUE



- 1 Insufficient vestibular depth and keratinised tissue after an augmentation procedure.
- 2 Application of a palatal keratinised strip toward the vestibulum, suturing of Geistlich Mucograft® over the previously augmented area where it is left exposed for healing.
- 3 Increased vestibular depth and keratinised tissue 3 months later.

Brochure "Innovative Treatment Concepts in Oral and Maxillofacial Surgery"



Also see the the Geistlich brochure on oral and maxillofacial surgery for more information on the sausage technique and the strip technique.

Vertical augmentation with granulate graft: A case report



Prof. Massimo Simion, Dr. Stefano Pieroni | Italy
Department of Periodontology and Implant
Restoration
Milan University

Large vertical augmentations require a staged approach that may consist of several treatment steps to ensure optimal hard and soft tissue results, as presented in this complex case.

The patient was a 55-year old female, non-smoker in good systemic and periodontal health.

Teeth 11, 21, 23, 24 had to be extracted due to extreme periodontal attachment loss. The extraction sockets were filled with Geistlich Bio-Oss® Collagen, and a free gingival graft was used to close the cavity and enhance clot formation. After 4 months, vertical bone augmentations were performed: two non-resorbable titanium-reinforced membranes protected grafts consisting of a 1:1 mixture of autogenous bone and Geistlich Bio-Oss®. The membranes were fixed by 4 bone fixation pins and sustained by a tenting screw, which was exposed over the portion corresponding to the vertical defect. Periosteal releasing incisions allowed the flap to be advanced coronally. The flap was sutured using horizontal mattress U-stitches to ensure proper flap apposition.

Six months later, machined implants were inserted, and a horizontal bone augmentation was performed using Geistlich Bio-Oss® and Geistlich Bio-Gide® to enhance the aesthetic outcome.

After another 4 months, the soft tissue thickness was augmented using a Geistlich Mucograft®. Two months later minimally invasive re-entry allowed the connection of the implant abutment and the beginning of prosthetic procedures.

Are there any special considerations?

Vertical bone augmentation by means of Guided Bone Regeneration (GBR) is a well-documented procedure that insures good long-term results¹⁻⁶. It allows a proper prosthetic rehabilitation with a crown length ideally proportioned to the adjacent teeth. However, the efficacy of this technique strictly depends on a standardised surgical protocol.

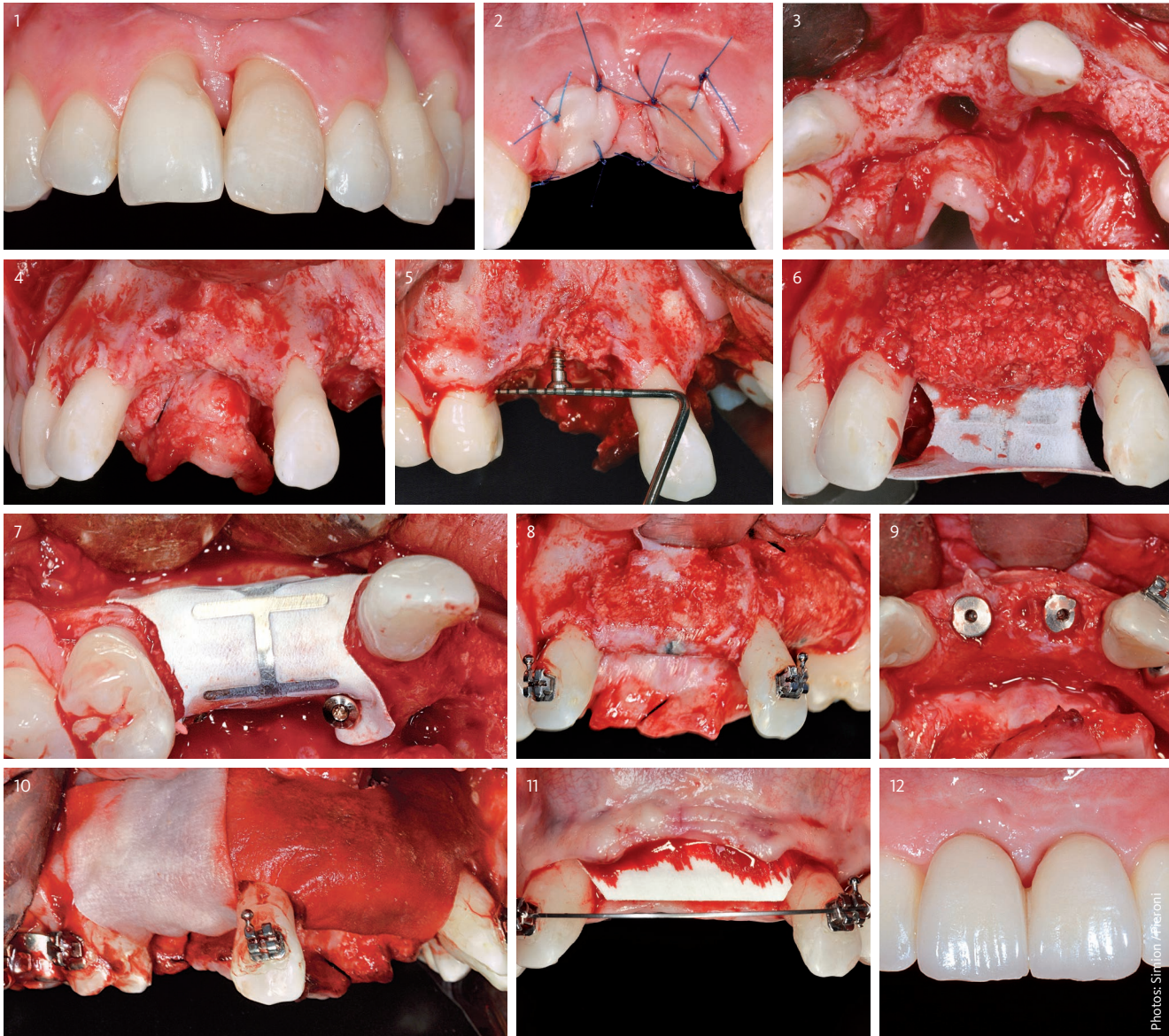
Ridge Preservation techniques may be performed to minimise soft tissue and bone contraction that generally follow tooth extraction⁷. Eventually, a horizontal GBR in relation to implant positioning and a soft tissue augmentation may be performed to increase tissue thick-

ness, resulting in a better blood supply and ultimately optimum long-term stability of the peri-implant tissues.

References

- 1 Simion M, et al.: Int J Periodontics Restorative Dent 1994; 14: 497-511.
- 2 Simion M, et al.: Clin Oral Implants Res 2007; 18(5): 620-9.
- 3 Tinti C, et al.: Int J Periodontics Restorative Dent 1996; 16: 221-229.
- 4 Parma-Benfenati S, et al.: Int J Periodontics Restorative Dent 1999; 19(5): 424-37.
- 5 Simion M, et al.: Clin Oral Implants Res 2001; 12(1): 35-45.
- 6 Jovanovic SA, et al.: Clin Oral Implants Res 2001; 12: 35-45.
- 7 Araujo MG, Lindhe J: J Clin Periodontol 2005; 32(2): 212-18.

CASE



CAPTIONS:

- | | | |
|--|---|--|
| <p>1 Teeth 11, 21, 23, 24 are irredeemable due to vertical bone loss.</p> <p>2 Sockets are filled with Geistlich Bio-Oss® Collagen and covered with free gingival grafts.</p> <p>3 4 Residual vertical and horizontal bone defects are still present at 4 months.</p> <p>5 The tenting screws are positioned to support the membranes.</p> | <p>6 A 1:1 mixture of Geistlich Bio-Oss® and autogenous bone is placed.</p> <p>7 Non-resorbable titanium-reinforced membranes are positioned and fixed with pins (2 palatal and 2 buccal for each membrane).</p> <p>8 After 6 months the membranes are removed to insert the implants. Note the regenerated bone.</p> | <p>9 Implant insertion in positions 11, 21, 23, 24.</p> <p>10 Horizontal bone augmentation using Geistlich Bio-Oss® and Geistlich Bio-Gide®.</p> <p>11 Before implant abutment connection, soft tissue thickness is increased using a collagen matrix (Geistlich Mucograft®).</p> <p>12 Final result: correct prosthetic rehabilitation avoiding excessive crown length.</p> |
|--|---|--|

Horizontal augmentations with blocks



Prof. Carlo Maiorana | Italy
Oral Surgery and Implant Department
University of Milan School of Dentistry
Fondazione IRCCS Policlinico Cà Granda

Surgeons can avoid complications with autogenous bone blocks if they use adequate incision techniques, rigidly fix the block and cover it with a suitable granulate bone substitute and membrane.

How to avoid problems in horizontal augmentations with block grafts

After tooth extraction the alveolar ridge undergoes a physiological resorption leading to narrowing. In the aesthetic area and for specific indications, such as lateral upper incisor agenesis or absence of lower incisors, the use of narrow diameter implants is considered a first choice option¹. But on a routine basis, a residual ridge width of at least 5 mm has to be present to allow the placement of a standard diameter implant (Ø 3.8 mm). In posterior areas clinicians should choose wider implants for prosthetic reasons, therefore, the lack of an ideal width is more frequent. One proven technique for optimising the horizontal ridge is autogenous block grafts. The main advantages of autogenous blocks are their osteoconductive, osteoinductive and osteoproliferative properties. However, since

the amount of bone is limited, this technique is not suitable for large defects and complete maxillary reconstructions.

Intraoral donor sites

Surgeons can harvest autogenous bone blocks from intraoral sites such as the chin or mandibular body under local anaesthesia in an outpatient procedure. Grafts from a mandibular symphysis consist of both cortical and cancellous bone. They allow the surgeon to increase the ridge width by up to 7 mm, while grafts from the mandible can be used to obtain only 3 to 4 mm in width due to the presence of the inferior alveolar nerve. In addition, they are composed of cortical bone only^{2,3}.

RISK: SUPERINFECTIONS

ANTIBIOTICS

A full dosage antibiotic therapy is used to avoid superinfections at the surgical site.

DRILLING OF RECIPIENT CORTICAL PLATE

The cortical plate should be drilled until it bleeds.

RIGID FIXATION

The block should be fixed with at least 2 screws.

IF EXPOSED: GRAFT COVERAGE

In absence of soft tissue inflammation, surgical corrections using sliding flaps, sometimes associated with connective tissue grafts, may allow the graft to be covered.

IF EXPOSED: REMOVAL OF NECROTIC PARTS

Necrotic portions of bone may have to be removed with a tungsten carbide bur.

Early exposure: the exposed bone has to be decorticated. Rinsing with antibiotic is recommended before closing the defect.

Late exposure: remove the necrotic portion until bleeding from the graft is noticed.

ANTI-EDEMA DRUGS**ADEQUATE INCISION TECHNIQUES**

Usually periosteal horizontal incisions are performed in a deep position from the inner portion of the flap and running from one releasing incision to the other. In doing so, the length of the flap can be increased up to 4 to 5 mm.

Larger reconstructions: Combinations with sliding partial thickness palatal flaps, detachment of the muscular fibres from the mylohyoid line and periosteal or vascularised connective tissue flaps⁶ are effective ways to totally passivate the flaps.

RISK: GRAFT EXPOSURE

AUTOGENOUS BONE BLOCKS

RISK: GRAFT RESORPTION**RISK: INSUFFICIENT GRAFT INTEGRATION / BLOOD SUPPLY****FILLING OF GAPS**

Gaps between the block and the recipient plate should be filled with autogenous bone chips.

BLOCK COVERAGE WITH GRANULES AND A COLLAGEN MEMBRANE^{4,5}

The block is covered with a thin layer of Geistlich Bio-Oss® and Geistlich Bio-Gide®. The granules allow new bone formation that balances the bone loss due to remodelling. Clinically, the original graft volume is maintained so that implants can be placed approximately 4 months later.

Risk: graft resorption

While autogenous blocks perform excellently in terms of quality of the reconstructed ridge, a main problem is the 5 to 20% graft resorption due to remodelling. One possibility for overcoming this resorption is to oversize the graft, but then closing the soft tissues without tension is a bigger challenge. An alternative procedure, that can be easily performed at the end of the augmentation surgery is to cover the block with deproteinised bovine bone granules and a collagen membrane^{4,5}.

Risk: graft exposures

In order to limit the risk of graft exposure, the flap margins have to overlap at least 3 mm to allow for a tension-free wound closure. In addition, surgeons should avoid ischaemia during suturing by using an adequate incision technique.

Even if the mentioned procedures are performed in the correct way, the risk of graft exposure cannot be 100% elimi-

nated. If exposure occurs during healing, surgeons should remove necrotic tissue and obtain soft tissue coverage to avoid major graft resorption or infections.

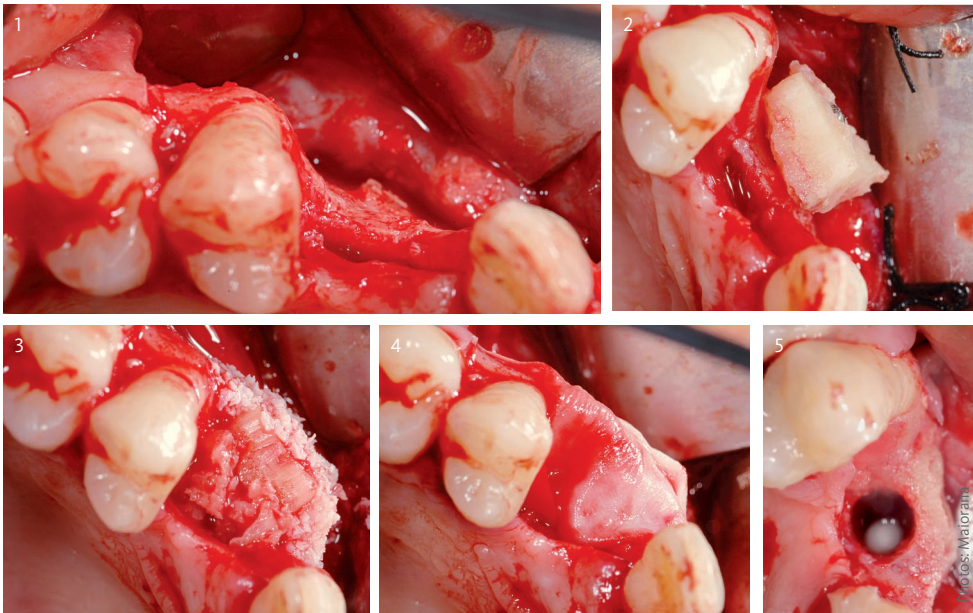
Risk: insufficient graft integration

If there are no exposures during healing, graft necrosis is an uncommon event. More frequently, problems may arise due to the in-growth of connective tissue into the gaps between recipient site and blocks: This may result in a lack of graft integration as well as an insufficient blood supply. The risks are minimised by drilling the recipient cortical plate until it bleeds, by rigidly fixing the block and by filling the gaps with autogenous bone chips. Adequate medication with antibiotics and anti-edema drugs is also recommended to reduce the complication risks.

References

- 1 Maiorana C, et al.: Clin Oral Implants Res 2014; 26: 77-82.
- 2 Anderson L, et al.: Oral and maxillofacial surgery; UK, 2010; 385-390.

- 3 Maiorana C, et al.: Bone augmentation procedures in the esthetic area with Bio Oss and BioGide; Italia Press Ed, Milan, 2009.
- 4 Maiorana C, et al.: Int J Periodontics Restorative Dent 2005; 25: 19-25.
- 5 Maiorana C, et al.: Open Dentistry J 2011; 25: 71-78.
- 6 Herford AS, et al.: J Oral Implantology 2011; 37: 279-85.



- 1 Initial clinical situation with insufficient horizontal ridge width.
- 2 After drilling the recipient cortical plate, the autogenous block graft from the symphysis is fixed rigidly with screws.
- 3 Gaps are filled with autogenous bone granules. The block is covered with a layer of Geistlich Bio-Oss®.
- 4 The graft is covered with Geistlich Bio-Gide®. The flap is closed without tension.
- 5 After 4 months the graft volume has been maintained and the implant is placed.

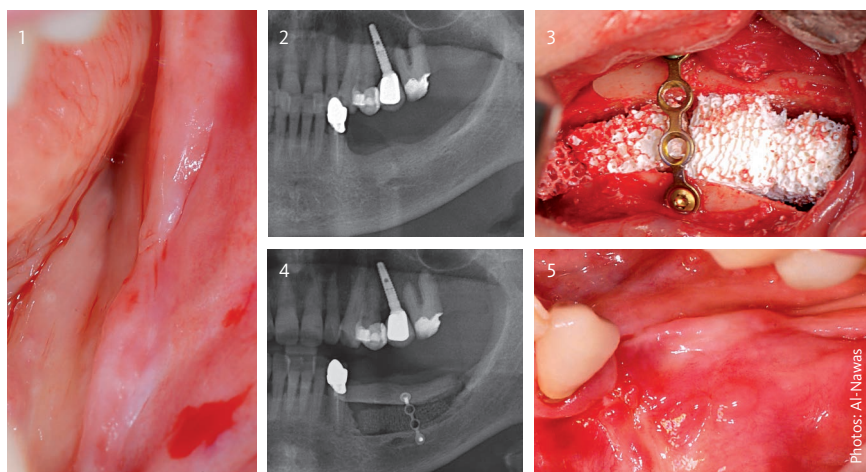
Vertical augmentation with the sandwich osteoplasty



Prof. Bilal Al-Nawas | Germany
Department of Oral and Maxillofacial Surgery,
Mainz University

Vertical augmentations are challenging. The sandwich technique facilitates soft tissue management and allows experienced surgeons to achieve good results in patients with greater vertical bone deficiencies.

When the ridge has to be augmented vertically to allow implant placement, sandwich osteoplasty offers important advantages over onlay techniques. Due to the repositioning of the keratinised soft tissue, no further soft tissue surgery is usually necessary. In addition, only native bone is located in the sensitive area crestally around the implant. Moreover, the grafted bone blocks are supported apically and coronally, thus facilitating bone in-growth and allowing considerable vertical gain. As a general prerequisite for this technique, a residual bone height of 4 mm above the inferior alveolar nerve should be available. The horizontal ridge width should be large enough to allow the insertion of a dental implant. Otherwise, the surgeon should exercise alternative



augmentation methods. Also, due to the rigid palatal mucosa, the technique is limited primarily to the lateral part of the mandible.

Planning

In the situation of reduced vertical dimensions, a CBCT (Cone Beam Computer Tomography) is often required to weigh the option of short implants versus a vertical bone augmentation. While short implants may also yield good long-term outcomes, a vertical augmentation will allow placement of implants with regular dimensions in an optimal three-dimensional position. This may facilitate the prosthetic treatment steps and improve the aesthetic result.

- 1 Occlusal view of the left lateral mandible with small band of keratinised mucosa and sufficient horizontal dimension.
- 2 Panoramic radiograph before augmentation demonstrating a height of 7 mm above the inferior alveolar nerve.
- 3 Lateral view after vestibular incision ("poncho flap"), osteotomy above the mental foramen, insertion of Geistlich Bio-Oss® block and a 1.5 mm mini plate (Medartis). The gaps were later filled with particulate Geistlich Bio-Oss®.
- 4 Post operative radiograph.
- 5 Clinical follow up. The keratinised mucosa has been elevated together with the cranial segment.

Nevertheless, the patient should be informed about possible complications such as graft failure or nerve lesions before surgery.

The key for success: flap preparation

In the sandwich technique, the soft tissue is left on the crestal part of the ridge. This allows optimal nutrition of the transposed bone.

A successful interpositional grafting procedure requires an adequate incision technique for the soft tissues that does not compromise blood supply.

Under local nerve block anaesthesia (buccal and inferior alveolar nerves), a subperiosteal poncho flap (repositioned perforated attached gingival flap) starting from the vestibulum is prepared and elevated. The critical step in this phase is the identification of the mental foramen. Afterwards the flap is raised close to the attached mucosa of the crest, while the crestal and lingual mucosa is left attached to the bone.

Osteotomy and interpositional grafting

The osteotomy above the nerve is performed using piezo surgery, since this technique allows higher precision and control than saws or burs in cutting just the bone. Palpating the tip of the piezo with a finger at the lingual sides can further help avoid damage to the soft tissue. Care is taken to keep the soft tissue attached to the cranial segment. After performing the osteotomy with a chisel, the mylohyoid muscle can easily be stretched.

The cranial segment can be elevated and stabilised by inserting a block of Geistlich Bio-Oss® – pre-shaped by piezo instruments – into the emerging

gap. With interpositional grafting in a sandwich osteoplasty, vertical augmentations of up to 8 or 10 mm can usually be achieved without problems.

Following the graft placement, a mini plate with short, self-tapping screws is attached to fix the bone and to avoid nerve damage. This fixation method is also used in more extensive maxillofacial surgery for internal and stable fixation of transposed bone elements.

The thick poncho flap can be closed with a double layer suture without further releasing incisions. The time until implant placement depends on the height of the vertical augmentation, but a healing phase of 6 months is sufficient in most cases. For implant placement, a crestal incision is performed, which allows the mini plate to be removed at the same time.

Pitfalls

The sandwich technique provides good success rates if there is careful patient selection and planning, and adequate surgical techniques are used. However, complications may arise from some typical pitfalls:

- › If the cranial segment is too thin, it might fracture during transposition.
- › A residual infection or osteomyelitis after extraction can lead to graft infection and failure.
- › Soft tissue and osteotomy problems may occur at the distal tooth due to the close spatial relationship.

FROM EARLY DRAWBACKS TO A SUCCESSFUL TREATMENT OPTION

Vertical augmentations of the mandible using a sandwich osteoplasty were first described in the seventies¹⁻². The technique at the time was subject to a major drawback: dental implants were inserted, simultaneously and surgeons tried to do “full jaw” augmentations. These approaches resulted in failures. Therefore, the technique was “forgotten” and onlay osteoplasties were performed instead – until 2006 Jensen et al. performed the sandwich osteoplasty in a localised jaw region and prior to implant placement⁴. The sandwich osteoplasty was used clinically with autologous grafts. Newer publications mainly focus on the use of Geistlich Bio-Oss® because patient morbidity is reduced, graft resorption is avoided and the risk of postoperative infections can be decreased⁵⁻⁶.

References

- 1 Härle F: Dtsch Zahnärztl Zeitschrift 1975; 30: 561.
- 2 Schettler D.: Fortschr Kiefer Gesichtschir 1976; 20: 61-63.
- 3 Stoelinga PJ, et al.: J Oral Maxillofac Surg 1986; 44: 353-60.
- 4 Jensen OT, et al.: J Oral Maxillofac Surg 2006; 64: 290-96.
- 5 Felice P, et al.: Eur J Oral Implantol 2008; 1(3): 183-98.
- 6 Felice P, et al: Clin Oral Implants Res 2009; 20(12): 1386-93.

The exciting future of regenerative dentistry




Prof. Alan Herford | USA
Oral and Maxillofacial Surgery,
Loma Linda University

Tissue engineering and regenerative medicine (TERM) is a highly multidisciplinary field in which bioengineering and medicine merge. Integrative approaches using scaffolds, cells, growth factors or gene therapy are developed to overcome today's limitations in augmentation procedures.

Patients with defects due to congenital disorders, trauma or tumor removal often suffer from serious functional and aesthetic deficiencies that strongly compromise their social lives. Current therapy options are highly invasive, associated with severe morbidity or are simply unavailable. However, the progress in technology has enabled advances. Promising techniques are now being studied¹ that may shift the frontiers in regenerative dentistry and medicine. TERM techniques include:

- › Injecting cells into the damaged tissue, either with or without a degradable scaffold.



3D printing may help to shift the frontiers in regeneration.

- › Growing a complete three-dimensional tissue to maturity in the laboratory and then implanting it into a patient.
- › Implanting a scaffold directly into the injured tissue and stimulating the body's own cells to regenerate the tissue.
- › Introducing a gene encoding a therapeutic protein into cells, which can then express the target protein.

Cells + scaffold + growth factors

Three components are needed for successful tissue engineering: cells (such as stem cells), scaffold or matrix (which provides a degradable physical base for cell growth), and growth factors. Simply put, the cells grow along a physical scaffold, and specific growth factors stimulate cell activity and differentiation into the desired tissue.

One of the first tissues to be engineered and used clinically is bone. Engineered bones may one day eliminate the need for more invasive therapy.

Stem cells

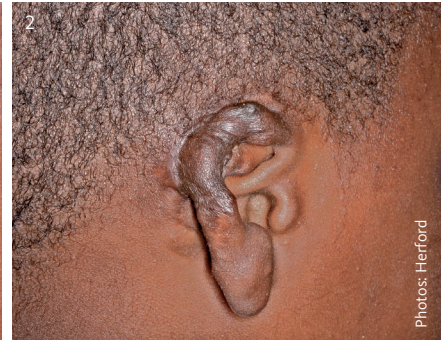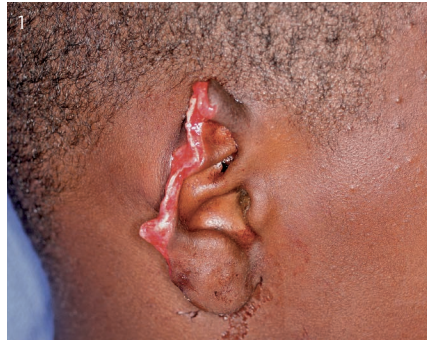Reconstruction of craniofacial and dental defects using mesenchymal stem cells avoids many of the limitations of both auto- and allografting. Clinical studies are underway using stem cells for alveolar ridge regeneration as well as long-bone defects.² Dental stem cells from the pulp, periodontal ligament, and associated healthy tooth structure have shown promise in treating a number of diseases.

3D scaffolds

A scaffold is necessary to enable cell growth. It should contain growth factors such as Bone Morphogenic Protein (BMP), fibroblast growth factors, and endothelial growth factors to aid in stem cell proliferation and differentiation. Furthermore, it should provide nutrients promoting cell survival and growth. The scaffolds studied have included natural or synthetic, biodegradable or permanent materials.

3D printing of tissue

Technological advances in biomaterials, printer technology and computer-aided design allow replacement tissues and organs to be “printed”. The idea is to use patient data, such as from a CT scan, to first create a computer model of the organ. This model is used to guide the printer as it prints layer-by-layer a three-dimensional structure made up of cells and the biomaterials to hold the cells together. This printer



Photos: Herford

- 1 A patient who sustained a traumatic loss of a portion of her ear.
- 2 A collagen matrix was used to regenerate the missing body part.

is unique in that it can use biomaterial gels as well as rigid polymers – so that any three-dimensional shape can be created. In addition, it can print proteins, growth factors and other liquids into the structure to help promote regeneration once the device is implanted. This device is still experimental and is being explored for organs such as the kidney and structured tissue such as the ear.

Challenge: vascularisation

Many challenges remain, however. For example, if an engineered tissue is placed into the body, it has to be vascularised quickly or the tissue will die. This presents a greater challenge in larger engineered tissues. The timing and appropriate doses of growth factors are still under investigation.

Next evolution

Researchers are also developing engineered skin, which will help treat massive burns, chronic wounds and missing soft tissue in the oral cavity. Skin and cartilage substitutes are available through regenerative medical techniques, and laboratory-grown tracheas, blood vessels and other tissues have been implanted into patients. Other tis-

sues that are at the early stages of engineering include heart valves as well as bladders. In fact, a whole bladder has been engineered and transplanted in a dog.³ The bladder appeared to be normal and demonstrated normal function. Nearly every body tissue is being engineered for future applications in medicine. As we continue on this exciting journey of exploration, thus expanding the frontiers of tissue regeneration, we should keep the words of Christopher Columbus in mind:

“You can never cross the ocean unless you have the courage to lose sight of the shore”.

Christopher Columbus

References

- 1 Nedel F, et al.: J Contermp Dent Pract. 2009; 10(4):90-6.
- 2 Bossu M, et al.: Scientific World Journal 2014; 2014:151252
- 3 Oberpenning F, et al.: Nature 1999 Biotechnology 17, 149 - 55.