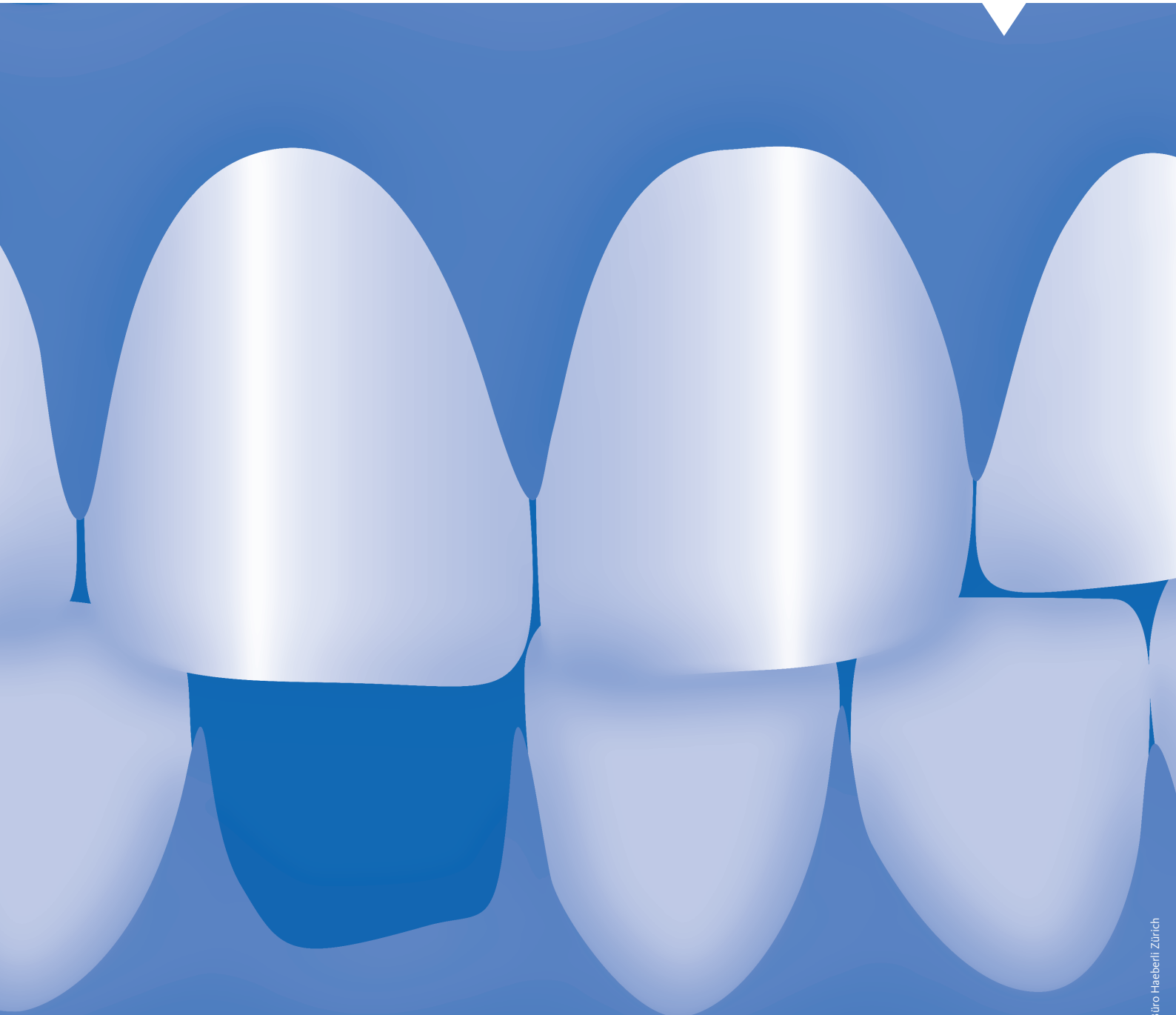


RIDGE PRESERVATION.

Each extracted tooth presents a new challenge.
What can Ridge Preservation measures achieve?



Extraction sockets: the key facts



Dr. Maurício G. Araújo | Brazil
Department of Dentistry
State University of Maringa

Following tooth extraction, how much surrounding bone is lost? Can this process be slowed? Our current understanding.

In a jaw that has been edentulous for years, the alveolar ridge can resorb completely¹. Also, single tooth gaps are subject to dramatic contractions. In order to describe such dimensional alterations following tooth extraction, the edentulous ridge has been measured in numerous studies, clinically, radiographically and using casts.

According to the Osteology Consensus Conference, the mean ridge reduction is 3.8 mm horizontally and 1.24 mm vertically^{2,3}.

Adaptation to a new, edentulous state

What are the reasons for bone resorption following tooth extraction? First we have to be clear that the jaw is made of basal bone and alveolar process. It is the bone of the alveolar process that is mainly resorbed. In addition, it is not the entire alveolar process but a significant part of it,

about 30% (for individual tooth gaps in the first year following extraction). The remaining jaw, the basal bone, is resorbed to a lesser extent, i.e., about 10%⁴. The amount of bone resorption depends on anatomical factors, site of extraction and function.

Often the bone of the alveolar process is made up of very thin socket walls, especially at the buccal aspect, and parts of the alveolar process are often outside the envelope of the jaw. In addition, since the purpose of the alveolar process is to support a tooth, once the tooth has been removed, bone is resorbed because the body adapts to the new, edentulous state.

Bone loss in posterior and anterior sites

The extent of bone loss varies according to the site and the patient. Our studies show that net loss of bone is greater in the posterior than the anterior regions. Fortunately, the posterior sites contain so much bone that resorption is often not a major clinical problem.

On the other hand, due to the limited amount of anterior bone, the loss of less bone in the anterior region can be problematic. As alluded to above, facial bone walls are very thin and often

lost completely after a tooth has been extracted. Accordingly, the net bone loss is lowest in the incisor region, but the percentage of bone reduction is the highest (37%).

Lack of bone vs. lack of volume

There is another phenomenon to be considered. Despite alveolar process and basal bone reduction, there is more bone after tooth extraction than before – because new bone is formed in the space previously occupied by the root.

Thus, frequently we will have bone enough to hold an implant, especially a narrow diameter implant. But to restore a tooth with implants, not only is bone necessary but also ridge volume to provide the mucosa profile for aesthetics.

Now, if we have enough bone for placing the implant but not enough volume, in reality we don't necessarily need more bone but any graft that could provide volume, whether it is a gingival graft, a soft-tissue matrix, a bone substitute or anything that is compatible and stable. However, the best-documented way to preserve volume after tooth extraction is Ridge Preservation with biomaterials.

Less bone loss through Ridge Preservation

Ridge Preservation prevents volume loss after tooth extraction, but not always 100%⁵. Results depend, again, on the tooth region and the patient. We have recently shown that, for the vast majority of patients, preserving ridge dimension provides enough bone tissue to place an implant in a proper 3-dimensional orientation and with an ideal amount of bone surrounding the implant⁶. Animal studies have shown that in extraction sockets Geistlich Bio-Oss[®] Collagen supports new bone formation, particularly in the cortical region, and contributes to ridge profile preservation^{7,8}. Given these studies, we can assume that Ridge Preservation modifies bone modelling and alleviates buccal bone loss⁹.

How long does Ridge Preservation last?

Many studies on Ridge Preservation are limited to a six-month observation period. There is, however, reason to believe that extraction sockets filled with Geistlich Bio-Oss[®] continue to be stable much longer. Long-term studies measuring lateral augmentations¹⁰ and sinus floor elevations¹¹ have revealed that, if there is no loss caused by inflammation, Geistlich Bio-Oss[®] preserves ridge volume long term. Further extraction socket studies would, however, be helpful in confirming this assumption.

References

- 1 Bergman B & Carlsson GE: J Prosthet Dent 1985; 53: 56–61.
- 2 Lang NP, et al.: 2012; Clin Oral Impl Res 23(Suppl 5): 39–66.
- 3 Hämmerle CHF, et al.: Clin Oral Impl Res 2012; 23(Suppl 5): 80–82.
- 4 Unpublished data
- 5 Araújo MG, et al.: Clin Oral Implants Res 2015; 26(4): 407–12.
- 6 Monica M, et al.: Clin Oral Implants Res (submitted)
- 7 Araújo MG, et al.: Int J Periodont Restorat Dent 2008; 28: 123–35.
- 8 Araújo MG & Lindhe J: Clin Oral Impl Res 2009; 20: 433–40.
- 9 Araújo MG, et al.: Periodontology 2000 2015; 68: 122–34.
- 10 Jung RE, et al.: Clin Oral Implants Res 2013; 24(10): 1065–73.
- 11 Traini T, et al.: J Periodontol 78(5): 955–62.
- 12 Januario AL, et al.: Clin Oral Impl Res 2011; 10: 1168–71.



These factors influence bone loss

Facial bony walls are frequently thinner than 1 mm¹², and these thin walls are almost exclusively bundle bone. Because it is a completely tooth-dependent structure, the bundle bone is resorbed after tooth extraction.

The extent of surgical trauma influences bone loss after tooth extraction, so there are good reasons not to extract teeth with dental pliers but with a periotome or vertical tooth extractor⁹.

There is no current agreement about whether the **extent of a flap** influences superficial bone resorption⁹.

Loss of functional stimulation of the bony walls is a confirmed factor contributing to bone loss after tooth extraction⁹.

The new thinking post tooth extraction



Prof. Ronald E. Jung | Switzerland
Center for Dental and Oral Medicine
University of Zurich



Immediate implantation, spontaneous healing or Ridge Preservation – these are the available options after a tooth has been extracted. Which option is the best, and when?

There is new thinking in implant dentistry, much like the new thinking that occurred with cariology some 50 years ago. Treatment in cariology used to involve the “Extension for prevention” approach: the more hard tooth substance that could be replaced with an amalgam filling, the less that could go wrong. But since the 1960s, dentists have made retention of hard tooth substance their aim. And between 1964 and today, a prevention program has helped reduce the prevalence of caries in Switzerland by over 90%. And a similar new thinking is happening today at the “alveolar process” level. Again, retention instead of replacement is the key. At conferences we should no longer be measuring ourselves against those who can regenerate the largest bone defects, but rather we should seek to impress others with our predictable and low-risk procedures. Because alveolar ridge preven-

tion has its part to play in this new approach, it is not just another technique in the treatment repertoire, it is much more significant.

Three options after tooth extraction

The first decision that the dentist must make: Should I let the extraction socket heal spontaneously, fill it with a bone replacement material or insert an immediate implant? The best procedure depends on different factors in day-to-day clinical practice: tooth location, the condition of the bone and soft tissue, as well as the patient's general state of health, his or her personal circumstances and financial situation, to name but just a few factors.

It is important that the treatment decision is discussed before the tooth is extracted. Depending on the option, the bone lost during the first four to six months is:

- › 50 % for spontaneous healing¹,
- › 56 % for immediate implantation²,
- › 15–20 % for immediate implantation with “gap filling”³, and
- › 15 % for Ridge Preservation⁴.

The advantages and disadvantages of the treatment options are depicted in **Fig. 1**.

The Modern Minimalist

Ridge Preservation:

Bone retention after tooth extraction, implantation or bridge restoration after 4–6 months

+ Non-invasive

Ridge Preservation is easy to perform and hardly invasive at all. It preserves the ridge volume for implants or bridge restorations.

Invasive GBR-measures are five-times less likely to be required after a Ridge Preservation⁹.

- No 100%-guarantee

Even Ridge Preservation cannot preserve 100 % of bone volume¹. A second augmentation may be necessary in the anterior maxillary area, if the aesthetics depend on 100 % bone volume.

When should the ridge be preserved?

In our clinic, Ridge Preservation is always carried out if no implant is placed within the first 8 weeks after tooth extraction (**Fig. 2, Page 10**).

There is another approach, however, which involves Ridge Preservation after every tooth extraction, if an implant or bridge restoration is planned. Above all, private practitioners claim that this pre-emptive measure gives them a greater degree of security. The alveolar ridge is always sufficiently

The Diva

Immediate implantation:

Implantation immediately after tooth extraction, potentially with simultaneous augmentation in the buccal gap ("gap filling")

+ Fewer interventions

The shorter treatment time and the reduced number of surgical interventions are major advantages of an immediate implantation. Also, blood-thinning medication taken by older patients has to be discontinued only once (lower risk).

- Comply with the indication

Immediate implantation can cause bone and soft tissue recessions. Anterior teeth should only be replaced with immediate implants when the buccal socket wall is sufficiently thick. Increased bone absorption can occur in the molar region⁷.

↳ Optimization:

Fill the gap between the buccal socket wall and the implant with a bone replacement material and cover the defect with a membrane.⁸ Some surgeons close the socket over the implant with a connective tissue transplant in order to gain additional volume.

broad, and one can feel certain about the quality of the regenerated bone before implant placement, so this approach is also legitimate.

The Classicist

Early implantation:

First spontaneous healing, then implant insertion 6–8 weeks after tooth extraction with simultaneous lateral augmentation

+ Tried and tested

The soft tissue has almost completely healed by the time of implantation, but not too much bone volume has been lost. The survival rate of implants in augmented bone is just as high as in native bone (approximately 92%)⁵. Histologically, well-integrated Geistlich Bio-Oss[®] particles show no signs of inflammatory activity⁶.

- Technically demanding

The implant procedure is as demanding as an immediate implant. As an implant has to be inserted into a socket, there is always the danger of placing the implant too far in the buccal direction.

The right procedure

The tooth should be extracted atraumatically after the soft tissue has been released using a desmoteome or scalpel. Orthograde apparatuses can help with the extraction, but they can be complex to use. In general you can say: the gentler, the better.

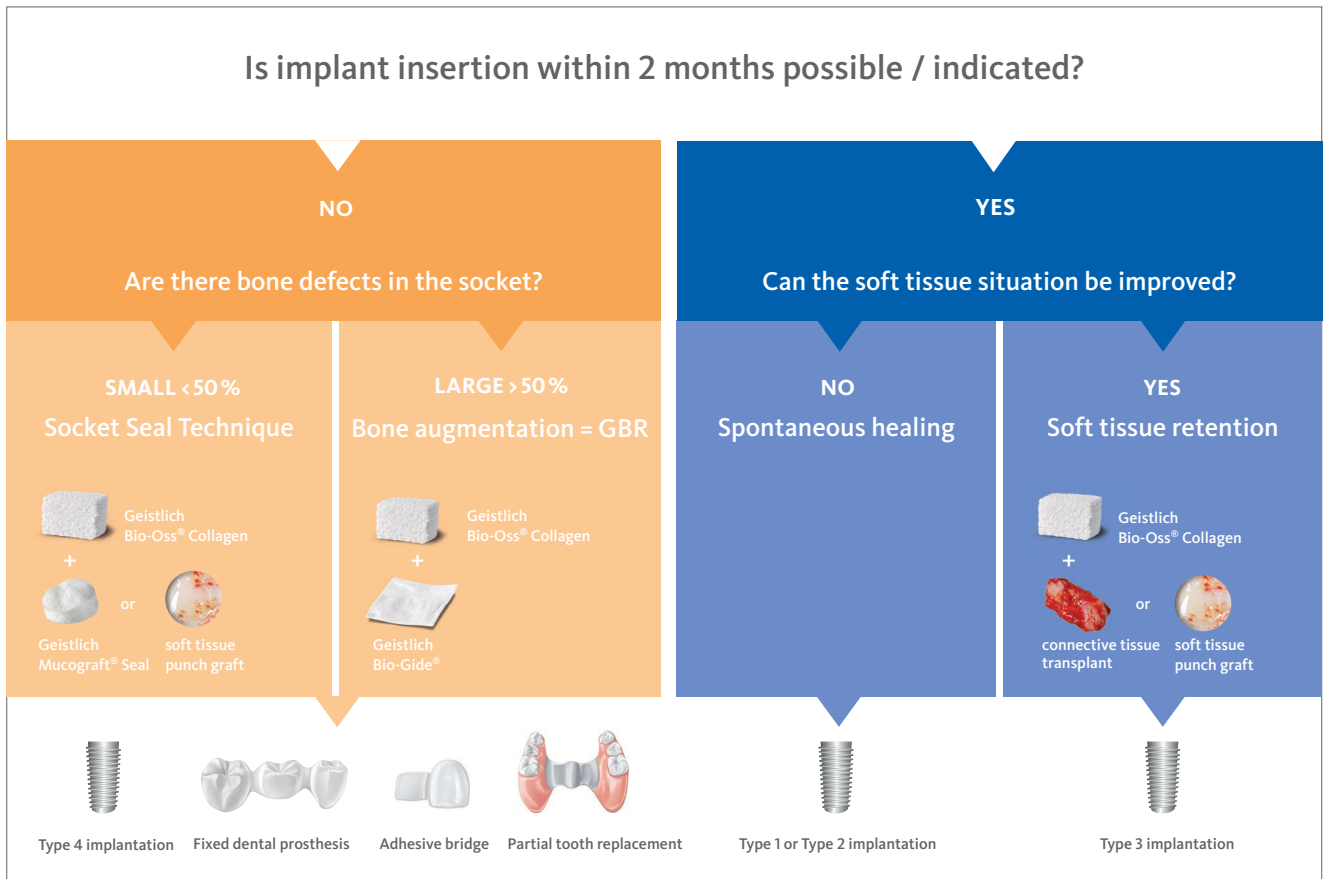
The extraction socket should then be curetted. This step must be performed carefully, as it can help prevent later

FURTHER TREATMENT

1 Three options after tooth extraction

complications. Using a periodontal probe – and a CBCT scan, if one is available – it is possible to establish whether the buccal socket wall is intact. The procedure depends on this diagnosis. If at least 50% of the buccal bone lamella has been resorbed, volume should be gained by contouring. After a flap has been prepared, the bone replacement material is poured into the socket and applied in a buccal direction. A collagen membrane is laid over the graft and ridge to stabilize the graft and prevent soft tissue invasion. Primary wound closure improves prognosis. The membrane itself does not need to be sutured.

If the buccal lamella is largely intact, the bone replacement material is poured into the socket without it being opened up, and the socket is then sealed – with a disc of collagen matrix Geistlich Mucograft[®] Seal or with an autologous soft tissue punch graft or a connective tissue palatal harvest graft. This "sealing" procedure has an advantage over the contouring approach, as the mucogingival border is not displaced. If a collagen matrix is used, which means that no harvest graft needs to be taken from the palate, then the procedure is even less invasive. If, however, the soft tissue has to be thickened, an autologous transplant is absolutely necessary.



2 Decisions after tooth extraction

There is very little convincing evidence for an approach using only bone replacement material, i.e., without a soft tissue transplant, wound closure, membrane or matrix. A randomized comparative study from our group has shown that, in the event of a Ridge Preservation without a collagen membrane or matrix, even more bone volume is lost than with spontaneous healing (bone material used: beta-tricalcium phosphate with a special coating)⁴.

When and how to optimize the soft tissue?

Above all, in the anterior maxillary region a sufficient quantity of keratinized soft tissue can be critical for aesthetics. At extraction, sometimes it is possible to predict when a larger bone

augmentation will be necessary later. In such cases, soft tissue management at the time of tooth extraction can be of enormous help. An autologous connective tissue or soft tissue punch graft from the palate, or a disc of collagen matrix can be used. After such a procedure, the soft tissue should be allowed to mature for at least two months before an implant is inserted.

References

- 1 Araújo MG, et al.: Periodontol 2000 2015; 68: 122–34.
- 2 Botticelli D, et al.: J Clin Periodontol 2004; 31(10): 820–28.
- 3 Chen ST, et al.: Clin Oral Implants Res 2007; 18(5): 552–62.
- 4 Jung RE, et al.: J Clin Periodontol 2013; 40(1): 90–98.
- 5 Jung, RE, et al.: Clin Oral Implants Res 2013; 24(10): 1065–73.
- 6 Jensen SS, et al.: J Periodontol 2014; 85(11): 1549–56.
- 7 Wagenberg B, Froum SJ: Int J Oral Maxillofac Implants 2006; 21(1): 71–80.
- 8 Araújo MG, et al.: Clin Oral Implants Res 2011; 22(1): 1–8.
- 9 Weng D, et al.: Eur J Oral Implantol 2011; 4 Supplement: 59–66.

Socket Sealing with collagen matrix



Dr. Stefan Fickl | Germany
Department of Periodontology
University Hospital Würzburg

Should the extraction socket be sealed with a soft tissue punch graft or with a collagen matrix? The matrix has some advantages over the autologous punch.

Studies over the past few years have clearly shown that Ridge Preservation significantly reduces ridge volume loss after tooth extraction. Animal and clinical trials have demonstrated that the combination of a xenogeneic bone replacement biomaterial (Geistlich Bio-Oss® Collagen) with an autologous soft tissue punch graft can achieve the most effective volume preservations^{1,2}.

But this technique is not without its clinical disadvantages, which include high patient morbidity and the danger of scar formation in the buccal region due to incomplete healing.

Preconditions for Socket Sealing

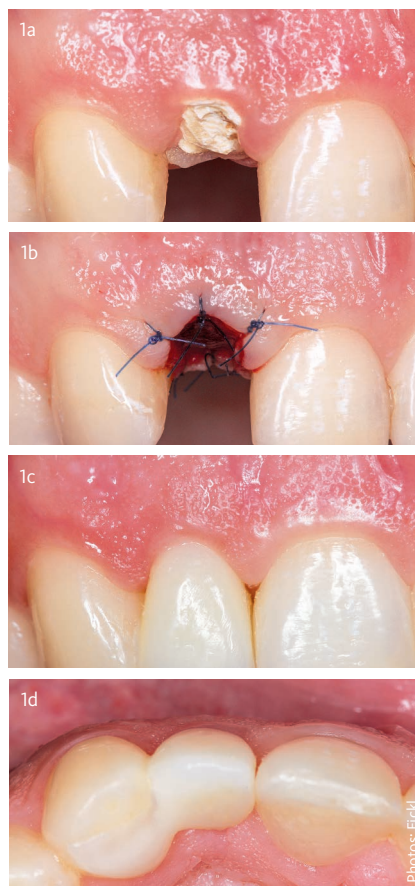
A xenogeneic soft tissue replacement material for the sealing of the extraction socket (Geistlich Mucograft® Seal) appears to provide Ridge Preservation results similar to an autologous soft

tissue graft³. At the same time, postoperative levels of patient morbidity are clearly lower (**Fig. 1 a,b**). It also appears that the collagen structure of Geistlich Mucograft® Seal reduces the risk of scar formation, ensuring a more pleasing tissue match with surrounding native tissues (“Blending”, **Fig. 1 c,d**). The preconditions for a successful application of the Socket Seal technique are an inflammation-free marginal soft tissue situation, precise suturing and an intact extraction socket with retained buccal bone lamella.

In these cases – and as found by the Geistlich Mucograft® Seal Advisory Board Meeting in February 2013 in Geneva – no additional barrier membrane is needed.

An early implantation time (8–10 weeks after extraction) is possible. If portions of the buccal bone lamella are dehisced, a membrane should also be used to protect the bone replacement biomaterial, and the healing time should be extended.

- 1a Clinical situation: tooth 12 is not worth retaining.
- 1b Situation after filling with Geistlich Bio-Oss Collagen® and sealing with Geistlich Mucograft® Seal.
- 1c Clinical situation after treatment with an adhesive bridge and pontic in Region 12.
- 1d Crestal view shows good volume retention through using Socket Sealing.



References

- 1 Fickl S, et al.: Clin Oral Implants Res 2008; 19: 1111–18.
- 2 Thalmair T, et al.: J Clin Periodontol 2013; 40: 721–27.
- 3 Jung RE, et al.: J Clin Periodontol 2013; 40: 90–98.

Ridge Preservation instead of sinus lift?



Prof. Giulio Rasperini | Italy
University of Milan
Dental Practice Prof. Giulio Rasperini
Piacenza

Interviewed by Dr. Mireia Comellas and Susanne Schick

Sinus floor elevation is still a major surgical intervention and is associated with the risk of complications. How can one avoid it?

Prof. Rasperini, the benefits of Ridge Preservation appear to be confirmed by the latest systematic reviews¹⁻⁵. In your opinion, what are the benefits of Ridge Preservation in the posterior region?

Prof. Rasperini: Ridge Preservation is performed in posterior regions in order to reduce the need for a sinus lift. The upper jaw has limited basal bone due to significant pneumatization of the sinus and, of course, incurs additional bone loss after tooth extraction. So, a sinus lift is needed to create sufficient bone for implant placement. However, preemptory Ridge Preservation reduces the need for bone regeneration at the time of implant placement.

You have investigated the effects of Ridge Preservation in the posterior area⁶. What was the goal of this study, and how was it designed?

Prof. Rasperini: Within this randomized study, Ridge Preservation with

Geistlich Bio-Oss[®] Collagen and Geistlich Bio-Gide[®] was compared to spontaneous healing. We focused on the posterior maxilla, which means first and second molars. Our goal was to evaluate the ridge alterations after tooth extraction and the need for a subsequent sinus lift.

Did you find an advantage for Ridge Preservation over spontaneous healing?

Prof. Rasperini: After 6-months the major benefit was a significantly reduced need for sinus floor elevations⁶. The bone is almost completely mature at that time, and a flapless implant placement can be performed easily, because of the ridge volume obtained with the grafting biomaterials. The simple procedure makes a big difference compared with sinus floor elevation, which is a major surgical procedure.

What is the patient benefit?

Prof. Rasperini: Most of the patients who undergo molar extractions are more than 70 years old. They are often on medications like Coumadin, Aspirin or other anticoagulants, and they can be diabetic. These are factors that influence wound healing and the outcome of any surgery. The patients appreciate avoiding a major surgery, and

treatment time is shortened, so they have less pain and, of course, they avoid possible post-operative complications.

You have also evaluated the healing process histologically. What did you find?

Prof. Rasperini: Our histological evaluation revealed normal healing with a lack of inflammatory cells. Geistlich Bio-Oss[®] Collagen as well as Geistlich Bio-Oss[®] appeared to be surrounded by newly formed bone. This is advantageous for the dentist: on the one hand, the bone is stable – due to the mineral component of the graft that resorbs slowly; and on the other hand, the biological activity of the new and vital bone promotes osseointegration of the implant.

Your publication includes a finding of “delayed bone formation process and incomplete resorption of bovine bone particles” at the grafted sites. How do you interpret this finding?

Prof. Rasperini: It is well known that the body's own cells incorporate the grafting granules in the bone remodelling processes⁶. In the case of the Geistlich bovine bone mineral particles, this process takes place over a long period of time.

Ideally, when the bone is mature, the newly formed bone of the regenerated area will be mineralised. With Geistlich Bio-Oss® we place mineralised particles in the socket from the beginning. After six to nine months, histopathology shows that biologically active tissues surround these particles, i.e., newly formed woven and lamellar bone⁶. With grafting we achieve ideal physical and mechanical results.

According to a study performed by Prof. Cattaneo's group⁷, less than 20% of Geistlich Bio-Oss® is still present after ten years. So at that time we have over 80% mature, mineralised bone.

You used Geistlich Bio-Gide® as a collagen membrane to protect the augmented site. What makes you sure that this membrane has the right barrier function for this indication?

Prof. Rasperini: Wound healing consists of three phases: first comes the inflammatory phase, which takes about three days, then the proliferative phase, which takes about 15 days, and finally the maturation phase, which continues over three months⁸. In the beginning a scaffold is needed that prevents any shrinkage of the tissue and graft loss. But after one month, every cell in the wound “knows” exactly what to do, and the barrier function is no longer needed. That's why Geistlich Bio-Gide® with its short barrier function is appropriate. The advantage of Geistlich Bio-Gide® compared to other non-resorbable membranes is that it does not interfere with vascularization and nutrition processes between the soft tissue flap and the underlying graft. Cells and blood vessels from the flap integrate with the membrane quickly and start to deliver nutrients and oxygen to the surgical site, contributing to the maturation of the graft and the healing process. A recently published paper from our group

- 1 Three months post-surgery. A large amount of Geistlich Bio-Oss® (BO) particles are surrounded by highly cellular, fibrous connective tissue (CT). No inflammatory infiltrate is detectable. NFB = newly formed bone (Magnification: 4 ×)
- 2 Nine months post-surgery. Remnants of the biomaterial are surrounded by newly formed bone (NFB) in lamellar shape as well as woven bone (WB) to some extent. (Magnification: 10 ×)



provides this evidence⁹. If, on the other hand, a non-resorbable membrane is used, the graft receives nutrition from the bone site only and lacks nutrition from the flap.

But there is another fact to be considered: how quickly the graft resorbs. Geistlich Bio-Oss® resorbs slowly and, thereby, preserves volume in the augmented site. Autologous bone, in contrast, resorbs quite quickly so that volume is lost. To compensate for this loss, a different type of membrane that resorbs slower than the scaffold is needed – not for the barrier function, but for volume stability. With Geistlich Bio-Oss® and Bio-Gide® we achieve the ideal combination of volume stability and barrier function.

References

- 1 Avila-Ortiz G, et al.: J Dent Res 2014; 93(10): 950–08.
- 2 Morjaria KR, et al.: Clin Implant Dent Relat Res 2014; 16(1): 1–20.
- 3 Horvath A, et al.: Clin Oral Investig 2013; 17(2): 341–63.
- 4 Vittorini Orgeas G, et al.: Int J Oral Maxillofac Implants 2013; 28(4): 1049–61.
- 5 Vignoletti F, et al.: Clin Oral Implants Res 2012; 23 Suppl 5: 22–38.
- 6 Rasperini G, et al. Int J Periodontics Restorative Dent 2010; 30(3): 265–73.
- 7 Sartori S, et al.: Clin Oral Implants Res 2003; 14(3): 369–72.
- 8 Polimeni G, et al.: Periodontol 2000 2006; 41: 30–47.
- 9 Pellegrini G, et al. Int J Periodontics Restorative Dent. 2014; 34(4): 531–39.

“Ridge Preservation simplifies treatment”



Dr. Dietmar Weng | Germany
Practice for Dentistry Böhm & Weng
Starnberg

Interviewed by Verena Vermeulen

Ridge Preservation creates better bone conditions for later implantation and provides more forgiving implant placement conditions for dentists with less experience, says Dr. Dietmar Weng.

To put the question as simply as possible: Isn't it always “Tooth out – bone replacement in”?

Dr. Weng: No, you really can't make such a generalization. It depends on several variables, for example: the treatment you are planning, the bone condition and the level of inflammation.

The German Society for Implants in its 2011 Consensus Conference noted that GBR-measures are five-times less likely to be needed at the time of the implantation if a Ridge Preservation was already performed¹. That is going to save a considerable amount of operating time and pain for the patient, don't you think?

Dr. Weng: Ridge Preservation, above all, is less traumatic for the patient than later GBR-measures. A periosteal inci-

sion must often be performed after a lateral bone augmentation so that the soft tissue can close without being under tension, which can cause both haematomas and swelling.

The time aspect, on the other hand, is of secondary importance. If one performs a Ridge Preservation, the tooth extraction takes longer, because one wants to remove the tooth more gently and damage the bone structure as little as possible. Ridge Preservation done correctly also takes time.

How can you tell beforehand whether a Ridge Preservation is necessary in order to avoid a later GBR?

Dr. Weng: According to Jan Lindhe's research, the thickness of the buccal bone lamella plays a role here. The loss of buccal-lingual alveolar ridge width with a thick buccal bone lamella, shall we say wider than 0.8 mm, is less than in sockets with a thin buccal wall. Unfortunately, the latter defects exist almost exclusively in the anterior maxillary area of bundle bone, which is resorbed after tooth extraction, at least up to a height of 2–3 mm from the ridge.

In practice, it is hard to measure the socket walls accurately either before or after an extraction, and without a flap it is also difficult to judge the bone situation.

In your view, when should Ridge Preservation be recommended?

Dr. Weng: I would always carry it out – both in the anterior and lateral tooth areas – if an implant is planned, but not when an immediate implantation is under consideration. And then I always fill the gaps between the implant and the socket walls!

Which situations do you find unsuitable for immediate implant placement?

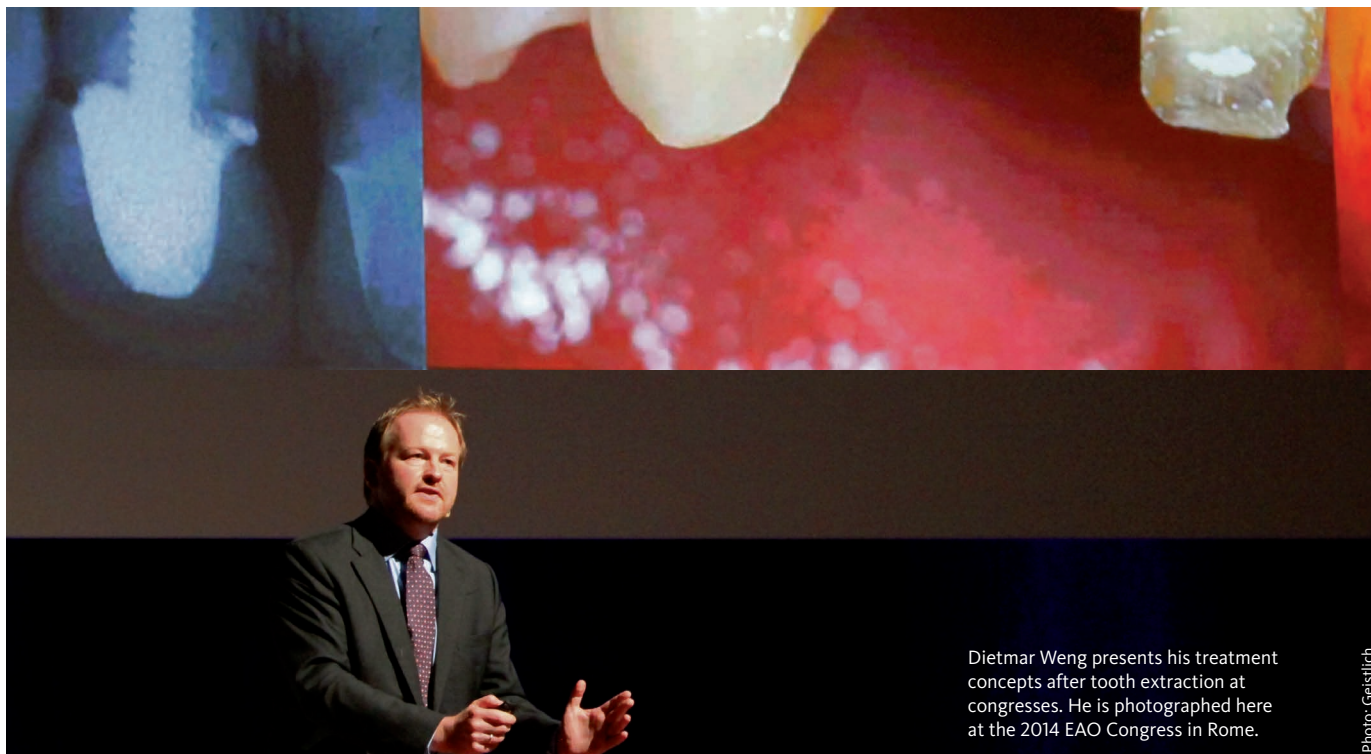
Dr. Weng: Molar sockets, severely inflamed sockets, or sockets with demonstrable wall dehiscences are not cases for an immediate implantation, in my view. I would carry out a Ridge Preservation first in such cases.

Does the patient's biotype play a role?

Dr. Weng: Over the years I have developed my treatments so that I can operate independently of biotype. As for Ridge Preservation, I would say it is just as effective for patients with thick or thin bony walls.

Would you also carry out a Ridge Preservation in order to preserve the volume under pontics?

Dr. Weng: Probably not, because of the financial considerations involved. When someone decides on a bridge reconstruction instead of an implant, he or she tends to do so on the



Dietmar Weng presents his treatment concepts after tooth extraction at congresses. He is photographed here at the 2014 EAO Congress in Rome.

Photo: Geistlich

grounds of cost. For such patients, Ridge Preservation is also a financial matter.

Often the person who removed a tooth does not insert an implant later himself, but refers the patient on to an oral surgeon...

Dr. Weng: Many dentists don't feel confident about implants, because they are associated with complex augmentations. But Ridge Preservation makes treatment much simpler. The measure

itself is uncomplicated and minimally invasive. And it creates a sufficiently wide alveolar ridge, which means that a later implantation can be performed by less experienced dentists.

So we should have "more confidence when it comes to implants"?

Dr. Weng: Yes. When you use a suitable procedure, the whole treatment from extraction to prosthetic restoration can be done in a minimally invasive way.

References

- 1 Weng D, et al.: Eur J Oral Implantol 2011; 4 Supplement: 59–66.

IMPRINT

Magazine for customers and friends of
Geistlich Biomaterials
Issue 2/2015, Volume 8

Publisher

© 2015 Geistlich Pharma AG
Business Unit Biomaterials
Bahnhofstr. 40
6110 Wolhusen, Switzerland
Tel. +41 41 492 55 55
Fax +41 41 492 56 39
biomaterials@geistlich.ch

Editor

Verena Vermeulen

Layout

Marianna Leone

Publication frequency

2 x a year

Circulation

25,000 copies
in various languages worldwide

GEISTLICH NEWS content is created with the utmost care. The content created by third-parties, however, does not necessarily match the opinion of Geistlich Pharma AG. Geistlich Pharma AG, therefore, neither guarantees the correctness, completeness and topicality of the content provided by third parties nor liability for damages of a material or non-material nature incurred by using third-party information or using erroneous and incomplete third-party information unless there is proven culpable intent or gross negligence on the part of Geistlich Pharma AG.

Ridge Preservation in the anterior maxilla: a case study



Dr. Beat Walkkamm | Switzerland
Praxis Walkkamm
Langenthal

A case series investigation of whether it is possible to insert an implant just four months after a Ridge Preservation.

A 75-year-old female patient was referred for the extraction of teeth 21 and 22. An implant restoration in region 21 (screw-retained) with an extension bridge was planned. Both teeth had gingival recessions, although the patient had a thick biotype. The patient had a deep smile line.

After the careful removal of tooth 21, the extraction socket was filled loosely up to the crestal edge of the socket walls with Geistlich Bio-Oss® Collagen. A disc of collagen matrix, Geistlich Mucograft® Seal, was adapted to the deepithelialised wound margins over the bone replacement material and stabilized with a mattress suture. Tooth 22 was initially left in situ and served as an anchoring point for the temporary Flieger crown x22.

The healing progressed smoothly. After three weeks, the epithelisation over the collagen matrix was complete. After four months, the implant (Straumann Bone Level NC Implant Roxolid SLActive) was inserted in the correct prosthetic position. The newly formed

bone had matured by this time, and there was sufficient primary stability. After a further two-month healing phase, the reopening took place, and a conical healing cap was inserted. The patient was referred back to the dentist treating her for the prosthetic restoration and the extraction of tooth 22. Two years later, the probe values around the implant were 3 mm. The extension of the crown (tooth 22) had no contact in the articulation. The patient was very happy with her treatment.

What should be taken into consideration?

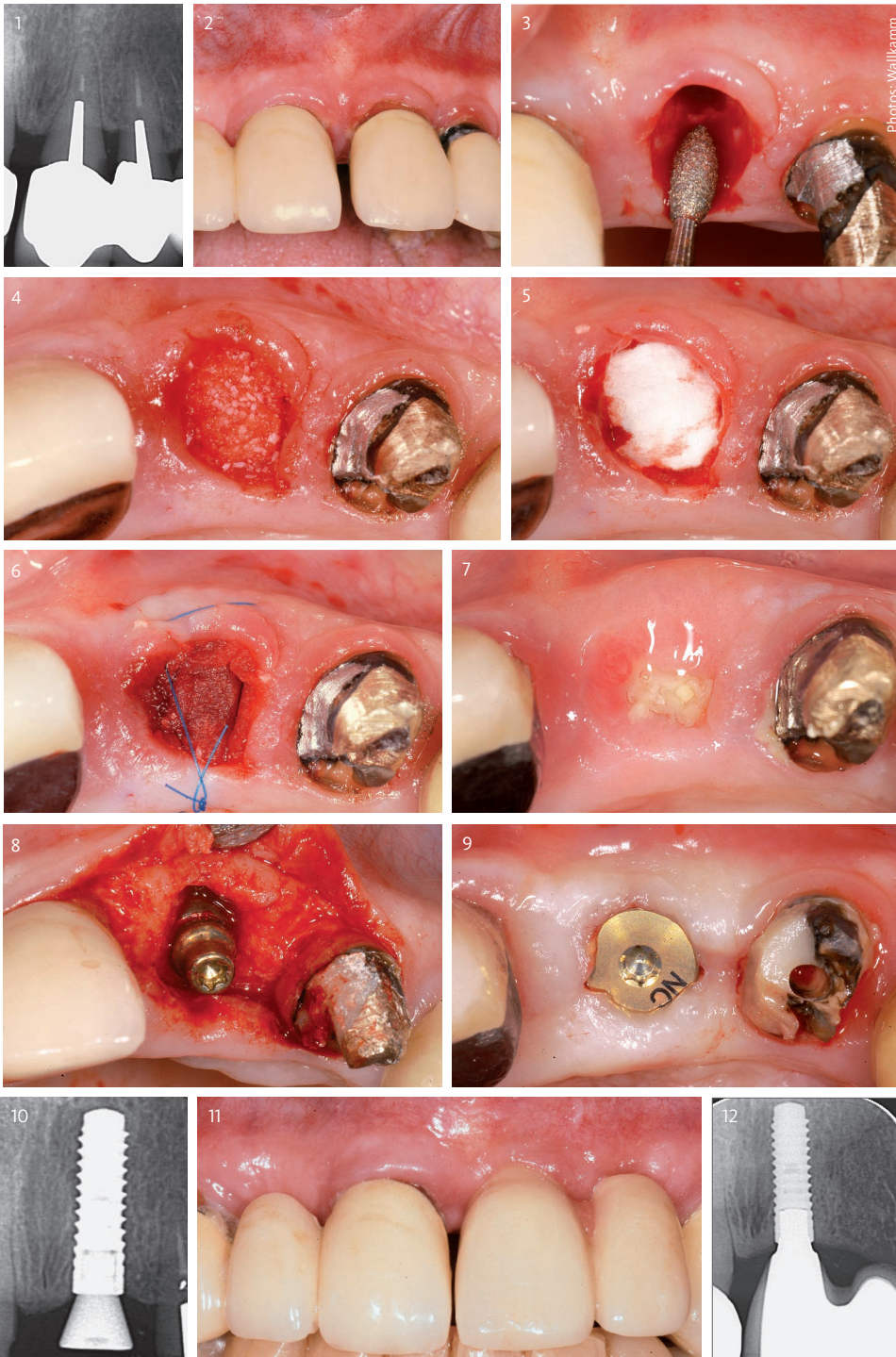The case is part of a case series, in which the effectiveness of Ridge Preservation in combination with a late implantation was tested. One of the objectives of the case series was to evaluate the earliest possible time for implantation after Ridge Preservation. For this reason, the implant was inserted after just four months, although this is a relatively early implantation time after bone regeneration with bovine bone replacement material.

A biopsy was taken in order to assess the condition of the bone after four months. The degree of maturity of the new bone was sufficient for a primary stable implant insertion.

Aftercare planning

Cooperation with the referring dentist is of great importance for a successful treatment. The patient's oral hygiene barely fulfilled the requirements for implant placement. We recommended that the dentist arranges more frequent recall appointments for professional tooth cleaning.

CASE



- 1 Radiograph of teeth 21 and 22, which were not worth retaining
- 2 Clinical situation of the area to be treated
- 3 De-epithelialisation of the sulcus after tooth extraction
- 4 Geistlich Bio-Oss® Collagen placed in the extraction socket
- 5 The extraction socket sealed with Geistlich Mucograft® Seal
- 6 Stabilisation suturing
- 7 Healing after one week
- 8 Installed implant with a sealing screw
- 9 New healing cap for the emergence profile after 2 months
- 10 Radiograph 2 months after implant insertion
- 11 Clinical situation 2 years after extraction
- 12 Radiograph 2 years after extraction