


AMIC® Chondro-Gide® in the Knee



More than
10 Years
of Clinical Success

About Geistlich Surgery

Geistlich Surgery produces innovative bio-derived matrix products for bone and cartilage, including Orthoss[®], Orthoss Collagen[®], and Chondro-Gide[®]. Our products leverage the body's own healing potential to regenerate bone and cartilage. Our focus is on helping people maintain and regain their quality of life.

Geistlich Surgery is a business unit of Geistlich Pharma AG, which is headquartered in Switzerland. Entirely family owned since 1851, the company develops, produces, and markets medical devices for regenerative medicine and pharmaceuticals. From research and development to marketing, our operations are fully integrated under one roof, which enables us to oversee and optimize all levels of our business.

Geistlich and Collagen

Geistlich was among the first pharmaceutical companies to apply collagen for medical use in the 1990s. With more than 160 years experience with bio-derived bone and collagen products, we applied our extensive knowledge of collagen and its biofunctionality to develop the first collagen membrane to foster regeneration by providing a protective environment for the cells and nutrients that are essential for regrowth.

As experts in bone and tissue regeneration, we see tremendous potential for collagen in the future of regenerative medicine. That is why we have dedicated a team of biochemists, materials scientists, process engineers, and other experts at our headquarters in Switzerland to focus exclusively on collagen, and to explore its other possible therapeutic applications.

Through close relationships with the medical and scientific community, we continue to share our knowledge and optimize our collagen-derived products. Finding ways to improve people's quality of life remains our larger goal.

Several studies report articular defects in 60–66% of knees undergoing arthroscopy for pain. Of these, 55% were larger than 2 cm² in size.¹

CONTENTS

1	AMIC [®] for Knee Cartilage Regeneration
2	Developed to Support Regeneration: Chondro-Gide [®] and AMIC
4	AMIC Chondro-Gide
6	Mini-Open Surgery
8	Arthroscopic Surgery
10	Clinical Summaries
12	Rehabilitation and Follow-Up Treatment
13	Geistlich Surgery

AMIC[®] for Knee Cartilage Regeneration

Your Challenge

As an orthopedic surgeon today, you face a growing number of treatment challenges. Patients are now living longer and are more physically active than previous generations. While many are staying active as they age, some are overweight.

With these changes in longevity and lifestyle, patients are using the major joints of their bodies more than ever. As a result, the number of patients with knee cartilage damage is rising. But with developments in diagnostic arthroscopy and Magnetic Resonance Imaging (MRI), early and precise detection and treatment is now possible.

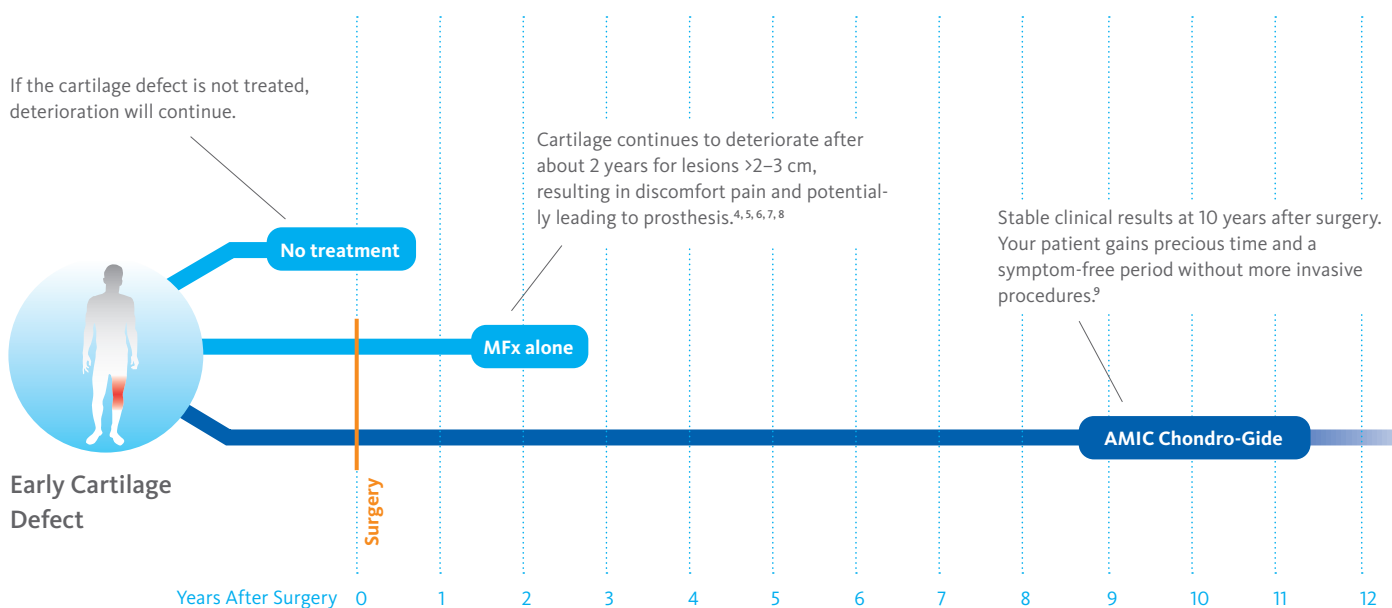
The Solution

Chondro-Gide[®], a bio-derived collagen membrane, combined with Autologous Matrix-Induced Chondrogenesis (AMIC) is a 1-step treatment for repairing cartilage lesions. Developed by Geistlich Surgery in collaboration with leading surgeons, AMIC uses bone marrow stimulation (BMS) in combination with Chondro-Gide to support the body's own healing potential.

The Results

Backed by more than 10 years of clinical success, AMIC Chondro-Gide is an effective and cost-effective^{2,3} treatment for repairing cartilage lesions, alleviating or preventing pain, and slowing the progression of damage.

REGENERATION OF CARTILAGE BUYS PRECIOUS TIME



Developed to Support Regeneration: Chondro-Gide® and AMIC®

Geistlich Pharma is a leader in the field of regenerative orthopedics, which leverages the body's own ability to repair bone and cartilage.

A Better Alternative to Standard MFX

Standard MFX is commonly used in cartilage repair surgeries to recruit mesenchymal stem cells and other key bone marrow components to the site of the defect to support the regeneration of cartilage tissue. In larger lesions¹⁰, the blood clot resulting from MFX is not stable enough to withstand shear forces in the joint.

AMIC Chondro-Gide addresses this problem by combining standard MFX with the use of a collagen membrane, which covers and protects not only the super clot but also the repair tissue.¹¹ Chondro-Gide is a biocompatible and fully resorbable porcine collagen membrane developed by Geistlich for use in AMIC Chondro-Gide, a one-step procedure that is backed by more than 10 years of positive clinical results.⁹

Effective for Both Large and Small Defects

AMIC Chondro-Gide was developed specifically to treat cartilage lesions in articular joint surfaces. While standard MFX is generally recommended for small chondral defects (<2 cm²), AMIC Chondro-Gide is an effective solution for larger defects.^{6, 11, 12, 13}

What Makes Chondro-Gide Unique¹⁴

- > Bio-derived, bilayer Collagen I/III membrane¹⁴
- > Biocompatible and naturally resorbed¹⁴
- > Easy to handle: supple and tear-resistant¹⁴
- > Can be glued or sutured¹¹
- > Compatible with a range of tissue regeneration techniques¹⁵
- > One-step procedure¹⁴

Bioengineered to Leverage the Body's Own Healing Potential

Chondro-Gide[®] is a porcine bilayer Collagen I/III membrane. It has a unique structure, being compact and smooth on one side and rough and porous on the other. This provides a protective environment for the stabilization of tissue repair.^{14,16}

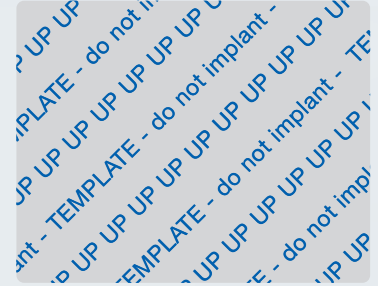CHONDRO-GIDE IS AVAILABLE IN THREE SIZES

The top layer of the membrane is marked with the word "UP" in one corner.

UP		
20 x 30 mm		
30 x 40 mm		
40 x 50 mm		

A STERILE ALUMINUM TEMPLATE IS INCLUDED

The size and shape of the membrane patch can be determined with the sterile aluminum template.




38 x 48 mm

A Barrier to Prevent Cell Diffusion^{14,17}

The smooth, compact top layer is also sturdy enough to protect the cells and newly forming cartilage from shear stress in the joint, while the cartilage regenerates and patients undergo rehabilitation.

A Rough, Porous Bottom Layer

This layer adheres to the defect, keeping the membrane in place. Cells that are released through Mfx or other marrow stimulation techniques attach themselves to this layer, where they proliferate and produce new tissue.^{15,18}



AMIC® Chondro-Gide®

AMIC Chondro-Gide is a minimally-invasive 1-step procedure that can be performed either by mini-open surgery, or in an arthroscopic manner.

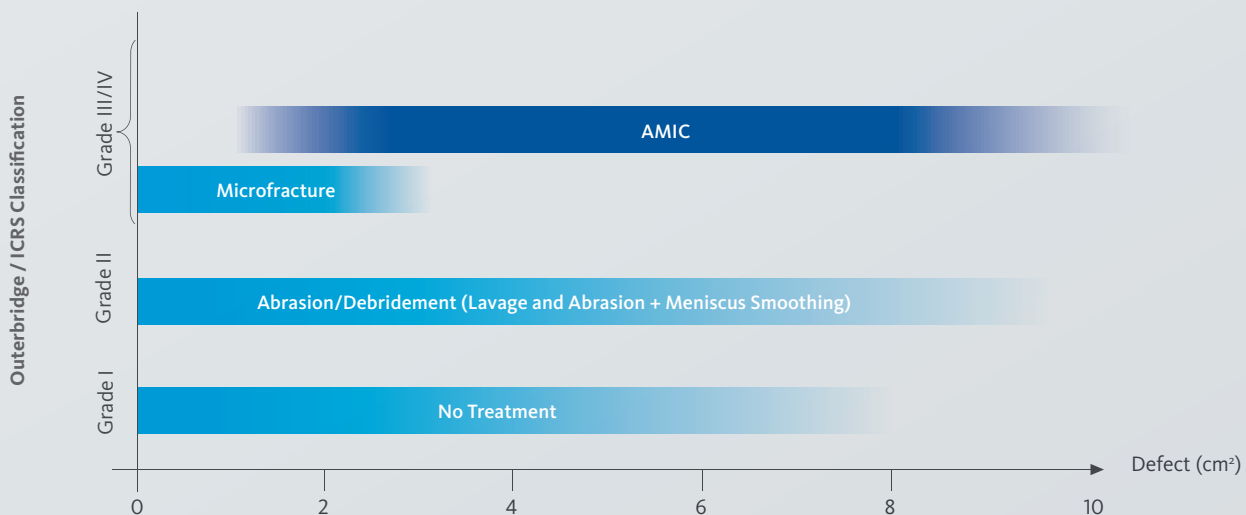
Developed by Geistlich Surgery in collaboration with leading surgeons in Europe, this technique has been effective in repairing chondral or osteochondral defects in the knee, talus, and hip.^{3,11,12}

The Benefits of Using AMIC Chondro-Gide

With both mini-open and arthroscopic techniques, the unique advantage of AMIC Chondro-Gide is that it supports the body's own potential to heal itself. Damaged cartilage is removed, and then the subchondral bone is microfractured or drilled to release supply of fresh, viable mesenchymal stem cells.

The membrane covers the defect and serves as a protective shield that contains the cells and minimizes the impact of shear forces on the delicate superclot. At the same time, it functions as the roof of a biological chamber that forms over the defect. The biocompatible collagen material provides an environment for cell growth¹⁴ and is replaced by new cartilage tissue over time.¹⁶

INDICATIONS FOR AMIC CHONDRO-GIDE



INTENDED USE²⁰

Chondro-Gide® is used to cover cartilage defects treated with autologous chondrocyte implantation (ACI) or bone marrow stimulation techniques (e.g., AMIC® – Autologous Matrix Induced Chondrogenesis) and to cover meniscal or osteochondral defects. Surgical approaches include arthrotomy or arthroscopy. The defects can be acute or chronic and be caused by a fall, accident, or other traumatic events. Defects are located at articular cartilage surfaces including hyaline cartilage in the knee, hip, ankle foot, wrist, elbow, and shoulder; and fibrous cartilage including meniscus.

The defects can be acute or chronic and be caused by a fall, accident, or other traumatic events. Defects are located at articular cartilage surfaces including hyaline cartilage in the knee, hip, ankle foot, wrist, elbow, and shoulder; and fibrous cartilage including meniscus.

LIMITATIONS ON USE / PRECAUTIONS

Contraindications

Chondro-Gide should not be used in patients with:

- > a known allergy to porcine collagen
- > acute or chronic infection at surgical site
- > acute or chronic inflammatory joint disease.

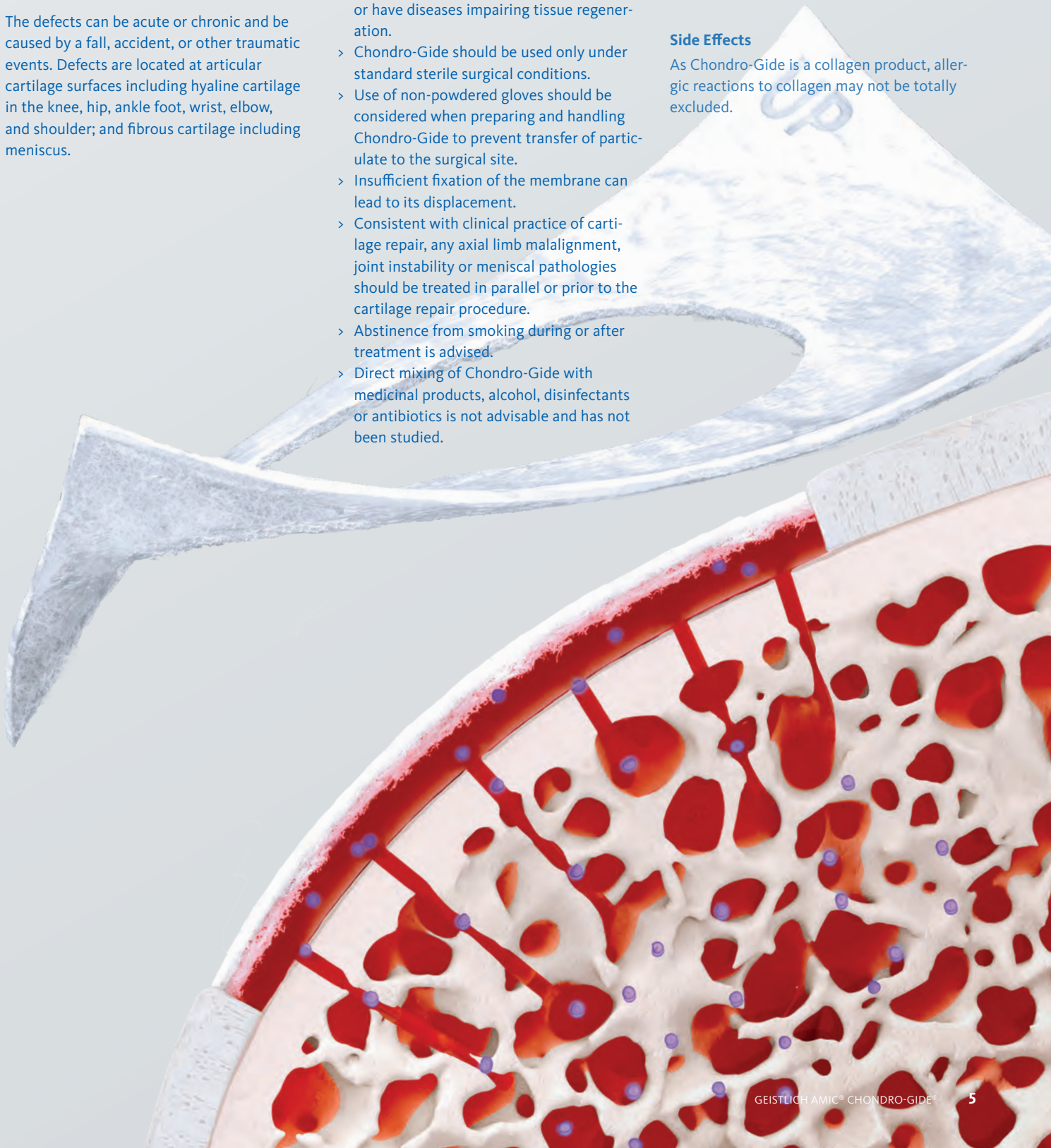
Precautions

- > Chondro-Gide should only be used by surgeons, familiar with cartilage and meniscal repair techniques.
- > Chondro-Gide should be used with special caution in patients who take medications or have diseases impairing tissue regeneration.
- > Chondro-Gide should be used only under standard sterile surgical conditions.
- > Use of non-powdered gloves should be considered when preparing and handling Chondro-Gide to prevent transfer of particulate to the surgical site.
- > Insufficient fixation of the membrane can lead to its displacement.
- > Consistent with clinical practice of cartilage repair, any axial limb malalignment, joint instability or meniscal pathologies should be treated in parallel or prior to the cartilage repair procedure.
- > Abstinence from smoking during or after treatment is advised.
- > Direct mixing of Chondro-Gide with medicinal products, alcohol, disinfectants or antibiotics is not advisable and has not been studied.

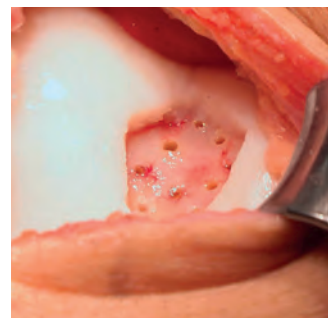
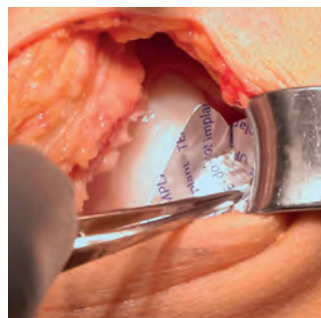
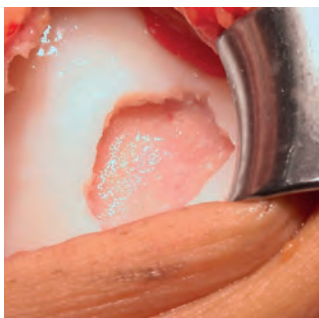
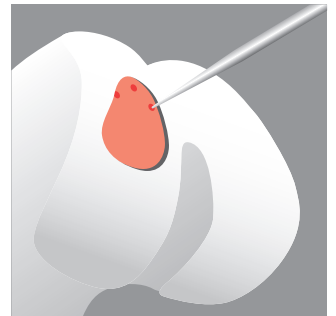

- > Intraoperatively, if there is need to remove the product, complete removal can be achieved. In the postoperative phase, complete removal may not be possible since the product is intended to resorb over time
- > There is no data available on the use of Chondro-Gide during pregnancy or lactation. For safety reasons, pregnant women and breastfeeding mothers should therefore not be treated with Chondro-Gide.
- > The safety and efficacy of Chondro-Gide have not been studied in children.
- > The template must not be implanted.
- > The product is intended for single patient, single surgery use, the product must not be re-sterilized. Any unused material should be discarded.

Side Effects

As Chondro-Gide is a collagen product, allergic reactions to collagen may not be totally excluded.



Mini-Open Surgery



Prepare the Surgical Site

Using a standard, minimally invasive anterior approach, open the knee joint. Remove damaged and unstable cartilage with a scalpel, curette, and spoon until a stable, perpendicular shoulder surrounds the defect.

Measure the Defect

Place the sterile aluminum template included with the Chondro-Gide® in the defect to obtain an exact impression of the defect. Cut out the imprint and transfer it onto the membrane. The side that was facing the defect must be placed on the smooth layer of the Chondro-Gide.

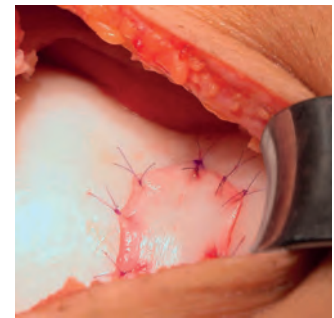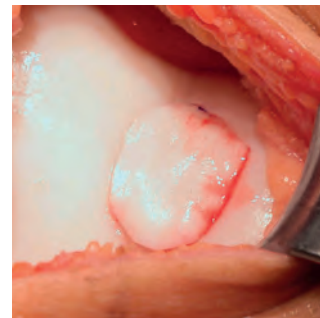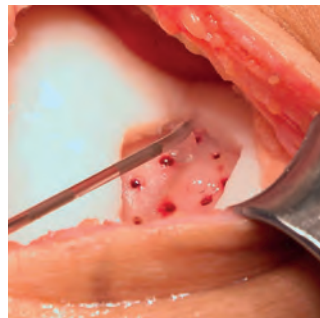
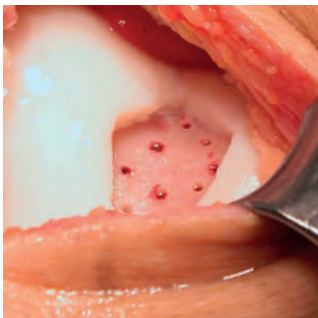
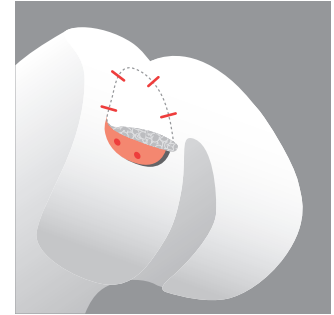

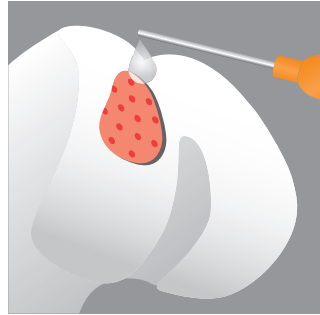

Trim the Chondro-Gide

When trimming the Chondro-Gide, remember to cut it 10–15% smaller than the template, as the area of the Chondro-Gide will expand once moistened. Supple and soft when wet, the membrane can be easily positioned to conform to defects of various shapes. If needed, use a sterile pen to lightly mark the smooth (top) layer that will face the joint cavity. The “UP” sign might not be visible any more once you have cut or hydrated the membrane.

Perforate the Bone

Use a sharp awl or drill to perforate the subchondral bone at the base of the lesion. Start at the periphery of the lesion and then move toward the center at intervals of 3–4 mm². With adequate cooling, antegrade drilling is also possible.

- ▶ Prior to surgery during diagnostic arthroscopy, carefully assess the size and classification of the defect. If necessary, carry out concomitant interventions, e.g., meniscal repair, alignment or stabilization.



Remove the Residual Tissue

Carefully remove the residual tissue and check for adequate subchondral bleeding.

Secure the Chondro-Gide®

Apply fibrin glue directly to the subchondral bone plate around the perforations.

Position and Glue the Chondro-Gide®

Place the Chondro-Gide into the defect with the rough (bottom) layer facing the bone surface.

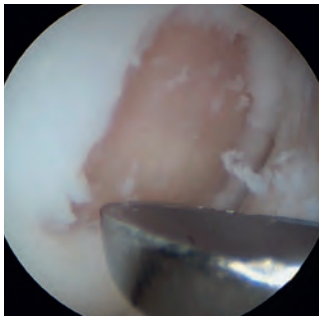Check the position of the membrane and close. Once the glue has set, after about 5 minutes, use a sharp scalpel to remove the excess fibrin glue carefully. To prevent delamination of the membrane, make sure the Chondro-Gide is flush with the edge of the defect.

Suturing Instead of Gluing

Using a TF-plus needle (inside-out technique, single stitches every 5 mm), attaching the Chondro-Gide with Vicryl or PDS 6/0 sutures is also possible.

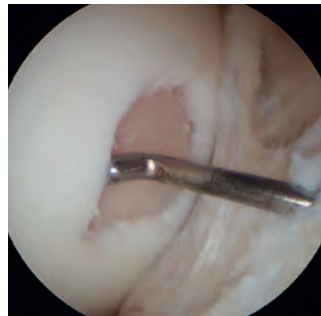► Check to make sure the membrane is positioned properly and stable by bending and extending the knee 10 times. To complete the surgery, carefully stop the bleeding, and suture the wound. If applying a drain, use a non-suction drain.

Arthroscopic Surgery




Prepare the Surgical Site

Use a sharp curette to remove cartilage fragments and create smooth vertical defect walls.



Measure the Defect Size

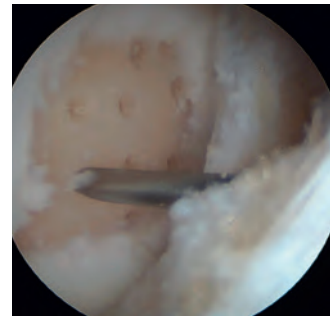Using a probe, measure the defect size. Turn the probe in different directions to determine the diameter and shape of the defect. Transfer the measurement in the same way onto the Chondro-Gide®.



Prepare the Chondro-Gide

Once the Chondro-Gide has been cut, moistened and is inside the joint, distinguishing the smooth from the rough layer might be difficult. Use a sterile pen to lightly mark the smooth (top) layer of the Chondro-Gide that will face the joint cavity.

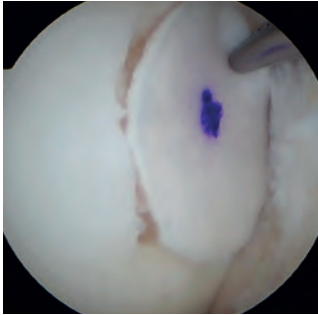When trimming the Chondro-Gide, remember to cut it 10–15% smaller than the defect itself, as the area of the Chondro-Gide will expand once moistened.



Microfracturing

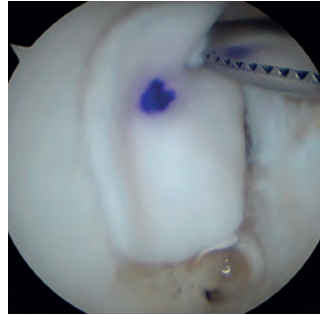
Using a 1.2 mm K-wire, perforate the subchondral bone at the base of the lesion. Working from the periphery of the lesion towards the center, insert holes at intervals of 3–4 mm. With a shaver, carefully remove tissue fragments. Alternatively, you can use an awl or nanofracturing to perforate the subchondral bone.

- ▶ Prior to surgery during diagnostic arthroscopy, carefully assess the size and classification of the defect. If necessary, carry out concomitant interventions, e.g., meniscal repair, alignment or stabilization.



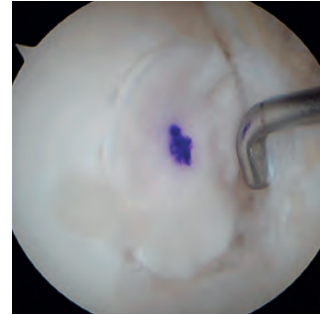Position the Chondro-Gide®

Use forceps or a clamp to place the membrane in the defect. To prevent delamination of the membrane, make sure the Chondro-Gide is sitting flush inside the defect.



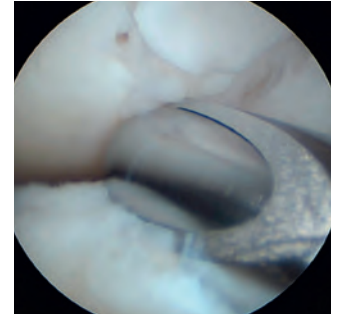
Apply the Glue

Inject fibrin glue into the space between the Chondro-Gide and the defect. Apply the glue at the top of the lesion and then let it flow to the lower part.



Secure the Chondro-Gide

Using an arthroscopic probe, tap the membrane into place.



Remove the Excess Glue

With a probe or a shaver, remove the excess fibrin glue.

NOTE

In addition to the wet arthroscopic technique illustrated above²², AMIC® can also be performed using a dry approach. The successful use of the dry technique has been described by different surgeons.^{23, 24} Choose wet or dry AMIC as you prefer.

- ▶ Check to make sure the membrane is positioned properly and stable by bending and extending the knee 10 times. To complete the surgery, carefully stop the bleeding, and suture the wound. If applying a drain, use a non-suction drain.

Consistently Positive Results at 10 Years

Mini-Open Surgery

A 10-year follow-up study by Kaiser et al.⁹ investigated the use of AMIC[®] in the treatment of chondral and osteochondral defects in the knee. Average Lysholm Scores and Visual Analogue Scores (VAS) for pain improved significantly when the pre-operative values were compared to the results at 2- and 10-year post-operative. Importantly, the improvement of these key scores was maintained over the 2 to 10-year follow up. This study demonstrated that AMIC offers significant improvement over the pre-operative status as well as long-term durability of results.

AMIC Shows Better Performance Than MFx Alone After 5 Years in a randomized, controlled study

In a multi-center, randomized, controlled 3-arm study by Volz et al. a significant deterioration in results was seen after 2 years when the treatment was MFx alone without Chondro-Gide[®].¹¹

All treatment groups in the 3-arm study showed significant improvement in the first year, followed by stabilization at 2 years. However, at 5 years, results of the AMIC Chondro-Gide patients were different from those of the MFx-only patients. Pain and function scores (ICRS and modified Cincinnati scores)

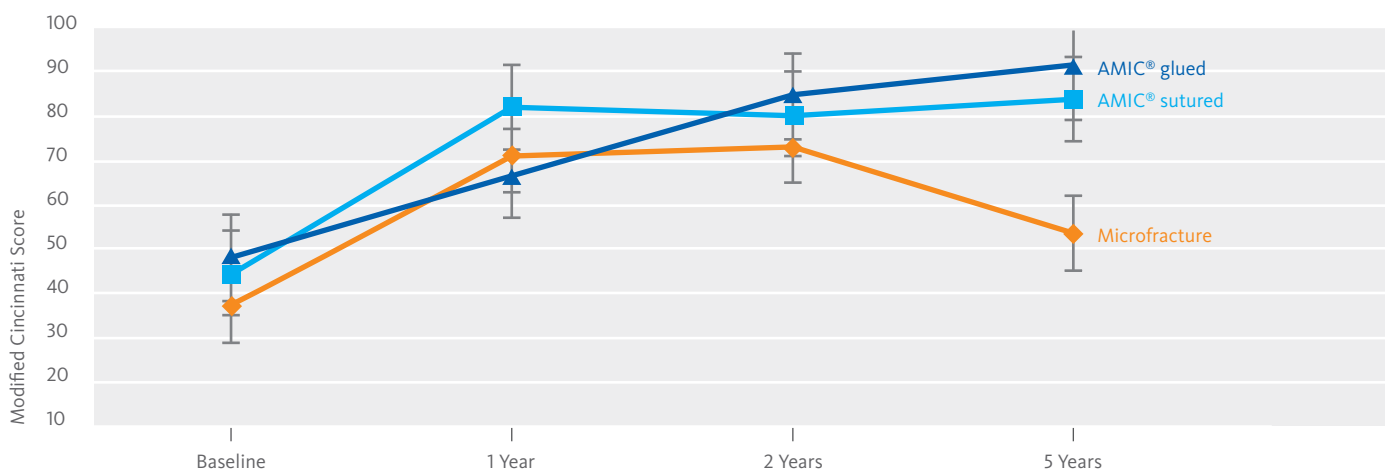
remained stable or even improved with AMIC, while pain and function scores for the MFx group decreased after 2 years (figure 1).

Overall, the results of this study are consistent with the observations from other published studies that show positive mid-to long-term clinical results for AMIC, while clinical outcomes for patients treated with MFx alone show a decline in performance after 2 years.^{4, 5, 25, 26}

First meta-analysis of 12 AMIC Chondro-Gide studies including 375 patients with a mean defect size of over 4 cm² demonstrates significant and sustainable improvement of knee function and pain¹³

Most recently, (2019) in a systematic review and meta-analysis of AMIC outcomes, the authors evaluated grade III/IV chondral and osteochondral lesions in the knee with a mean defect size of 4.24 cm². The meta-analysis included 12 studies and compared VAS, Lysholm and IKDC scores between baseline and follow-up after 1 or 2 and more than 3 years. It demonstrated that the use of AMIC Chondro-Gide in defect sizes, which are above the recommended threshold for MFx, significantly reduced pain and improved function from baseline to follow-up. The clinical outcomes suggested that AMIC provides a clinical benefit for at least 5 years, some of the studies even show stable results after 7 years. This publication is the first me-

FIGURE 1: FUNCTIONAL STATUS OVER TIME¹¹



ta-analysis of a one-step cartilage repair technique with only one scaffold used (Chondro-Gide®).¹³

Significant and sustainable improvement of knee function and reduction of pain at 7 years

A retrospective analysis by Schiavone Panni et al.² noted that AMIC® was effective when treating full-thickness knee cartilage defects larger than 2 cm². Over an average 7-year follow-up, patients consistently showed significant clinical and functional improvement based on their International Knee Documentation Committee (IKDC), MRI, and Lysholm scores.

ACI-C and AMIC Chondro-Gide provide equally good results after 2 years

Most recently, Fossum, et al., (2019) conducted a prospective, randomized, controlled study to assess the outcomes of ACI-C and AMIC in chondral and osteochondral defects of the distal femur and patella. At 1 and 2 years, the mean function and pain scores were compared with baseline scores and showed significant improvement. No significant differences were seen between the outcomes of the ACI-C and AMIC techniques. The authors concluded that AMIC could be considered a clinically equal, but less expensive alternative to ACI-C, as AMIC is a 1-step procedure therefore far less resource-intensive.²⁷

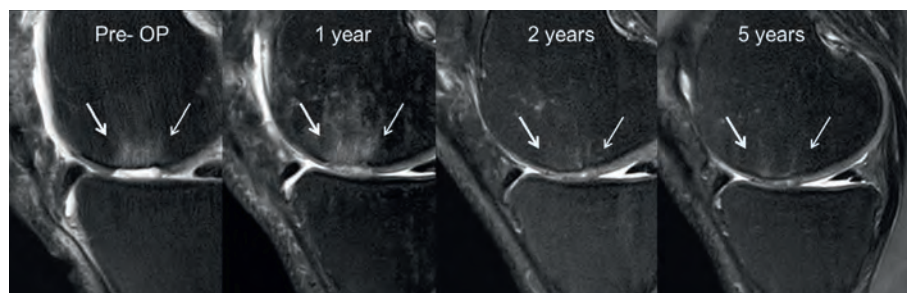
Arthroscopic Surgery

Arthroscopic Technique Equally Positive as Mini-Arthrotomy with AMIC Chondro-Gide

In a retrospective study, Schagemann et al.²² compared the clinical outcomes of AMIC Chondro-Gide procedures that were performed as either arthroscopic or mini-open surgeries. The study followed patients for 2 years.

According to the patients' Visual Analog Scale (VAS) pain scores, Lysholm scores,

FIGURE 2: CARTILAGE DEFECT REPAIR AFTER AMIC®



MRI (1.5T) follow-up at 1, 2, and 5 years after AMIC® shows progressive defect filling (20 × 20 mm, see arrows).¹¹ Image from Volz et al. CC BY 4.0

and Knee injury and Osteoarthritis Outcome Scores (KOOS), both surgical approaches yielded equally positive results.

Repairing Patellar Cartilage Lesions with AMIC Chondro-Gide

In another 2017 study, Sadlik et. al.²⁴ analyzed 12 patients who had undergone arthroscopic surgery using AMIC Chondro-Gide to repair patellar cartilage lesions. The Sadlik study assessed patients before surgery and at an average follow-up time of 38 months. Both clinical and radiological results improved significantly, according to criteria including KOOS, International Knee Documentation Committee (IKDC), Visual Analog Scale (VAS), Magnetic Resonance Observation of Cartilage Repair Tissue (MOCART) scores, and MRI.

Using augmented Mfx in combination with Chondro-Gide, both arthroscopic and mini-open have been shown to be successful treatments for more than 10 years. Using augmented Mfx with Chondro-Gide makes this technique even more effective, with enhanced healing and stability.

Beyond Microfracture

Designed to be used in combination with Mfx and Autologous Chondrocyte Implantation (ACI), Chondro-Gide is equally well-suited to be used with other bone marrow stimulation techniques.^{28,29} The unique bilayer structure

of the membrane is key. With a porous and a cell-occlusive layer, Chondro-Gide acts as both a cover or wrapper that encloses cell-rich material while also providing a protected environment for regeneration.

A review by Lee et al.³⁰ on AMIC and related techniques in the knee also documents the trend to add concentrated bone marrow-derived mesenchymal stem cells (MSCs) and Platelet-rich plasma, alone or in combination.

Bone marrow has been shown to be a possible source of multipotent stem cells with chondrogenic potential and can be harvested during the same surgical procedure. Gobbi et al.³¹ used bone marrow-derived MSCs and Chondro-Gide for large full-thickness chondral lesions of the knee. They demonstrated lasting post-operative results up to 3 years.

Another approach, presently in Phase II, uses nasal chondrocytes. They can be easily accessed and demonstrated their capacity to support articulate cartilage repair.¹⁷ Cells from a nose biopsy are seeded and expanded on the Chondro-Gide, the structure of which is perfect for this tissue culture approach. It allows a simple loading of the cells on the rough layer, while the smooth cell occlusive layer keeps the cells in place. The cultured tissue is then sutured into the cartilage lesion site. First clinical results showed statistically significant improvements in all categories.¹⁷

Rehabilitation and Follow-Up Treatment

Within a few days after surgery, patients can begin partial weight-bearing, supporting a small amount of weight (up to 50%) using the operated leg. However, they should not try full weight-bearing for approximately 6 weeks. Patients should take a gradual approach to increasing activity, but by 6 months after surgery, most should be able to resume their regular sports activities.

Key factors in determining whether a patient has recovered and can return to sports activities are whether the patient's state of healing has been accurately assessed, and whether the patient is ready to resume an active lifestyle.

As objective and subjective measures of healing often yield contradictory results, using both presents challenges in managing patient expectations.

In 2016, researchers correlated the results of subjective assessments, such as International Knee Documentation Committee (IKDC) and Lysholm scores, with objective isokinetic tests in patients who had undergone arthroscopic AMIC® in the knee. The results showed that while both objective and subjective measures were useful in monitoring a patient's overall rehabilitation progress, the IKDC and Lysholm tests were particularly useful in determining a patient's general state of recovery and readiness to return to sports activities.³²

Postoperative Rehabilitation after Cartilage Repair in the Knee

Stationary Phase

- > Prior to first mobilization, position the knee post-op in full extension in a splint and foam splint.
- > Mobilization on the first day by a physiotherapist
- > CPM/Kinetec: start with 30°/0/0 for ca. 2 hours/day (restricted by pain)

General (Depending on Availability)

- > Individual therapy during the first 12 weeks
- > Lymphatic drainage as needed to reduce excessive swelling
- > Hydrotherapy starting from week 6
- > Targeted medical training, including gait training from week 8

Active, Weight-Bearing

- > W 0–2 sole contact using crutches
- > W 3–4 partial weight bearing on crutches 10–15 kg
- > W 5–6 partial weight bearing on crutches 10–15 kg
- > W 6–7 transition to full weight bearing

(Femoro-patellar) Gentle Treatment with Corresponding Angles for the First 6 Months

- > Extension in open chain: 90°–40°; full flexion in open chain
- > From W 8: squat / 3 flex 0°–40°
- > From W 12: leg press 0°–60°

Passive Mobilization

- > W 0–1 ROM 30°/0/0
- > W 2–3 ROM 60°/0/0
- > W 3–4 ROM 90°/0/0
- > W 5–6 ROM 120°/0/0
- > CPM/Kinetec at home for ca. 3 hrs/d
- > Bicycle ergometer without resistance (max. 90°) from week 6 on: increase progressively from week 8 on (restricted by pain)

Muscle Build Up/Proprioception/Coordination

- > Optimize quadriceps innervation immediately
- > Increase of load bearing mainly in closed kinetic chain
- > Increase progressively from W 8 on (below pain threshold)

Active Mobilization

- > W 0–2 ROM 30°/0/0
- > W 3–4 ROM 60°/0/0
- > W 5–6 ROM 90°/0/0

Bandage/Orthesis

- > First 4–6 weeks in order to ensure limitation of movement, thereafter progressive reduction

Sports

- > M 2 post-op walking on soft surface
- > M 2 post-op cycling
- > M 6 post-op jogging
- > M 6 post-op mountain biking

W = week, ROM = range of motion, M = month, hrs/d = hours per day

Note: This is only an example of a plan that was developed by an orthopedic surgeon (M. Steinwachs, Sport Clinic, Zürich, 2018).^{33,34} There is no agreement on one standardized algorithm in literature or among orthopedic societies.¹⁹

Geistlich Chondro-Gide®

Regulatory approvals for Geistlich Chondro-Gide vary by country.

To learn more about product availability please visit www.geistlich-surgery.com or contact the Geistlich distributor in your region.



Membrane

Template, do not implant

- 1 HJELLE, K., et al. Articular cartilage defects in 1,000 knee arthroscopies. *Arthroscopy*, Sep 2002, 18(7), 730-734. (Clinical study)
- 2 SCHIAVONE PANNI, A., et al. Good clinical results with autologous matrix-induced chondrogenesis (Amic) technique in large knee chondral defects. *Knee Surg Sports Traumatol Arthrosc*, 2018 Apr 26(4):1130-36 (Clinical study)
- 3 WALTHER, M., et al. Scaffold based reconstruction of focal full thickness talar cartilage defects. *Clinical Research on Foot & Ankle*, 2013, 1-5. (Clinical study)
- 4 MITHOEFER, K., et al. The microfracture technique for the treatment of articular cartilage lesions in the knee. A prospective cohort study. *J Bone Joint Surg Am*, Sep 2005, 87(9), 1911-1920. (Clinical study)
- 5 GOYAL, D., et al. Evidence-based status of microfracture technique: a systematic review of level I and II studies. *Arthroscopy*, Sep 2013, 29(9), 1579-1588. (Review of clinical studies)
- 6 FONTANA, A., et al. Sustained five-year benefit of autologous matrix-induced chondrogenesis for femoral acetabular impingement-induced chondral lesions compared with microfracture treatment. *Bone Joint J*, May 2015, 97-B(5), 628-635. (Clinical study)
- 7 GAO, L., et al. Early loss of subchondral bone following microfracture is counteracted by bone marrow aspirate in a translational model of osteochondral repair. *Nature Scientific Reports*, 2017, 7:45189. (Pre-clinical study)
- 8 FRANK, R.M., et al., Failure of Bone Marrow Stimulation Techniques, *Sports Med Arthrosc Rev*, 2017, 25 (1) (Review of clinical studies)
- 9 KAISER, N., et al. Clinical results 10 years after AMIC in the knee. *Swiss Med Wkly*, 2015, 145 (Suppl 210), 43S. (Clinical study)
- 10 MITHOEFER, K., et al. Clinical Efficacy of the Microfracture Technique for Articular Cartilage Repair in the Knee. An Evidence-Based Systematic Analysis. *AJSM*, 2009. (Review of clinical studies)
- 11 VOLZ, M., et al. A randomized controlled trial demonstrating sustained benefit of Autologous Matrix-Induced Chondrogenesis over microfracture at five years. *Int Orthop*, Apr 2017, 41(4), 797-804. (Clinical study)
- 12 JANNELLI, E., et al. Arthroscopic treatment of chondral defects in the hip: AMIC®, MACI, microfragmented adipose tissue transplantation (MATT) and other options. *SICOT J*, 2017,3(43). (Clinical study)
- 13 STEINWACHS, M.R., et al. Systematic Review and Meta-Analysis of the Clinical Evidence on the Use of Autologous Matrix-Induced Chondrogenesis in the Knee. *Cartilage*. 2019:1947603519870846. <https://www.ncbi.nlm.nih.gov/pubmed/31508990> (Review of clinical studies)
- 14 Geistlich Pharma AG data on file (Bench test)
- 15 KRAMER, J., et al. In vivo matrix-guided human mesenchymal stem cells. *Cell Mol Life Sci*, Mar 2006, 63(5), 616-626. (Clinical study)
- 16 GILLE, J., et al. Cell-Laden and Cell-Free Matrix-Induced-Chondrogenesis versus Microfracture for the Treatment of Articular Cartilage Defects: A Histological and Biomechanical Study in Sheep. *Cartilage OnlineFirst*, January 7, 2010, doi:10.1177/1947603509358721 (Pre-clinical study)
- 17 MUMME, M., Nasal chondrocyte-based engineered autologous cartilage tissue for repair of articular cartilage defects: an observational first-in-human trial. *Lancet*, 2016, 388 (10055) 1985-1994. (Clinical study)
- 18 FULCO, I., et al. Engineered autologous cartilage tissue for nasal reconstruction after tumour resection: an observational first-in-human trial. *Lancet*, Jul 26 2014, 384(9940), 337-346. (Clinical study)
- 19 Niemeyer, P., et al., Significance of Matrix-augmented Bone Marrow Stimulation for Treatment of Cartilage Defects of the Knee: A Consensus Statement of the DGOU Working Group on Tissue Regeneration, *Z Orthop Unfall*, 2018 DOI-<https://doi.org/10.1055/a-0591-6457>
- 20 Chondro-Gide® IFU 2019, Geistlich Pharma AG (Review of clinical studies)
- 21 STEADMAN, J.R., Microfracture Technique for Full-Thickness Chondral Defects: Technique and Clinical Results. *Operative Techniques in Orthopaedics*. 1997. 7(4), 300-304. (Clinical study)
- 22 SCHAGEMANN, J., et al. Mid-term outcome of arthroscopic AMIC for the treatment of articular cartilage defects in the knee joint is equivalent to mini-open procedures. *Arch Orthop Trauma Surg*, Jan 22 2018. (Clinical study)
- 23 PIONTEK, T., et al. All-arthroscopic AMIC® procedure for repair of cartilage defects of the knee. *Knee Surg Sports Traumatol Arthrosc*, May 2012, 20(5), 922-925. (Clinical study)
- 24 SADLIK, B., et al. Biological reconstruction of large osteochondral lesions of the talar dome with a modified "sandwich" technique-Midterm results. *Foot Ankle Surg*, Dec 2017, 23(4), 290-295. (Clinical study)
- 25 KNUSTSEN, G., et al. A Randomized Multicenter Trial Comparing Autologous Chondrocyte Implantation with Microfracture: Long-Term Follow-up at 14 to 15 Years. *J Bone Joint Surg Am*, Aug 17 2016, 98(16), 1332-1339. (Clinical study)
- 26 KREUZ, P. C., et al. Results after microfracture of full-thickness chondral defects in different compartments in the knee. *Osteoarthritis Cartilage*, Nov 2006, 14(11), 1119-1125. (Clinical study)
- 27 FOSSUM, V., et al. Collagen-Covered Autologous Chondrocyte Implantation Versus Autologous Matrix-Induced Chondrogenesis: A Randomized Trial Comparing 2 Methods for Repair of Cartilage Defects of the Knee. *Orthopaedic Journal of Sports Medicine*. 2019;7(9) (Clinical study)
- 28 VOLPI, P., et al. Treatment of chondral defects with AMIC technique (Autologous Matrix Induced Chondrogenesis) compared to AMIC enhanced by concentrated bone marrow, ICRS Meeting 2009 (Clinical study)
- 29 STEINWACHS, M.R., et al. Matrix-associated chondroplasty: a novel platelet-rich plasma and concentrated nucleated bone marrow cell-enhanced cartilage restoration technique, *Arthroscopy Techniques*, 2014, (3) 2, pp e279-e282 (Clinical study)
- 30 LEE, Y. H., et al. Autologous Matrix-Induced Chondrogenesis in the Knee: A Review. *Cartilage*, Jul 2014, 5(3), 145-153. (Review of clinical studies)
- 31 GOBBI, A., et al. One-step surgery with multipotent stem cells for the treatment of large full-thickness chondral defects of the knee. *Am J Sports Med*, Mar 2014, 42(3), 648-657. (Clinical study)
- 32 PRUSINSKA, A., et al. A summary of the process of rehabilitation of patients after knee full arthroscopic amic (autologous matrix-induced chondrogenesis) based on biomechanical evaluation results in the respective steps 6, 12 and 24 months after surgery. *Knee Surgery, Sports Traumatology, Arthroscopy*, May 01 2016, 24(Supplement 1), 4-114. (Clinical study)
- 33 STEINWACHS, M., et al., Scientific Evidence Base for Cartilage Injury and Repair in the Athlete, *Cartilage*, 2012, 3(Suppl. 1) 11S-17S, DOI: 10.1177/1947603511415841 (Review of clinical studies)
- 34 STEINWACHS, M., et al., Regenerative Knorpeltherapie, *Orthopädie und Unfallchirurgie*, 2014, OE279-301 OEDOI: <http://dx.doi.org/10.1055/s-0033-1357981> (Review of clinical studies)



www.geistlich-surgery.com

Headquarters Switzerland
Geistlich Pharma AG
Business Unit Surgery
Bahnhofstrasse 40
CH-6110 Wolhusen
Phone +41 41 492 55 55
Fax +41 41 492 56 39
surgery@geistlich.com
www.geistlich-surgery.com

France
Geistlich Pharma France SA
Parc des Reflets
165 avenue du Bois de la Pie - BP 43073
FR-95913 Roissy CDG Cedex
Phone +33 1 48 63 90 26
Fax +33 1 48 63 90 27
surgery@geistlich.com
www.geistlich.fr

Germany
Geistlich Biomaterials
Vertriebsgesellschaft mbH
Schneidweg 5
D-76534 Baden-Baden
Phone +49 7223 96 24 0
Fax +49 7223 96 24 10
surgery@geistlich.de
www.geistlich.de

Italy
Geistlich Biomaterials Italia S.r.l
Via Castelletto, 28
I-36016 Thiene VI
Phone +39 0445 370 890
Fax +39 0445 370 433
surgery@geistlich.com
www.geistlich.it

Brazil
Geistlich Pharma do Brasil
Av. Brig. Faria Lima
1461 - 13 andar - cj. 131/134
01452-002 São Paulo - Brazil
Phone (11) 3097-2555
Fax (11) 3097-2550
info@geistlich.com.br
www.geistlich.com.br

Stable Results Over 10+ Years

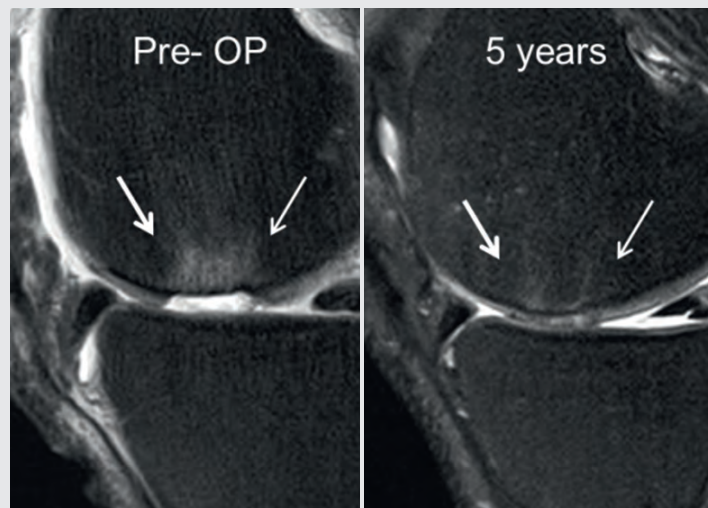


Image adapted from Volz et al.¹¹ CC BY 4.0

To start using AMIC® Chondro-Gide® to alleviate or prevent patient pain and slow the progression of damage, contact your local Geistlich representative.